

# Prevention of abdominal aortic aneurysm progression by oral administration of green tea polyphenol in a rat model



Shuji Setozaki, MD,<sup>a</sup> Kenji Minakata, MD, PhD,<sup>a</sup> Hidetoshi Masumoto, MD, PhD,<sup>a</sup> Shingo Hirao, MD,<sup>a</sup> Kazuhiro Yamazaki, MD, PhD,<sup>a</sup> Koichiro Kuwahara, MD, PhD,<sup>b</sup> Tadashi Ikeda, MD, PhD,<sup>a</sup> and Ryuzo Sakata, MD, PhD,<sup>a</sup> *Kyoto, Japan*

## ABSTRACT

**Objective:** Inflammation-mediated elastin destruction in the aortic medial layer is related to progression of abdominal aortic aneurysm (AAA). Epigallocatechin-3-gallate (EGCG), a major component of green tea polyphenols, reportedly increases elastin synthesis in vitro and may possess anti-inflammatory effects. We used a rat model to investigate whether EGCG could prevent AAA progression.

**Methods:** AAA was induced with administration of intraluminal elastase and extraluminal CaCl<sub>2</sub> in male rats. Rats were randomly divided into a control group (n = 30) and an EGCG group (n = 30). In the EGCG group, an EGCG solution (20 mg/d) was administered orally to each rat from 2 weeks before AAA induction and continued 4 weeks beyond induction.

**Results:** The abdominal aortic diameter was significantly smaller in the EGCG group than in the control group on day 28 ( $2.9 \pm 0.2$  vs  $2.3 \pm 0.1$  mm;  $P < .0001$ ). The medial layer wall thickness and elastin content were significantly greater in the EGCG group than in the control group on day 28 ( $68.4 \pm 13.6$  vs  $46.7 \pm 13.4$   $\mu$ m [ $P < .001$ ] and  $20.3 \pm 4.6$  vs  $9.5 \pm 3.6\%$  [ $P < .0001$ ], respectively). Gene expression levels of tropoelastin and lysyl oxidase were significantly higher in the EGCG group immediately before AAA induction, indicating promoted elastoregeneration by EGCG administration (tropoelastin:  $0.59 \pm 0.36$  control vs  $1.24 \pm 0.36$  EGCG [ $P < .05$ ], lysyl oxidase:  $0.77 \pm 0.45$  control vs  $1.34 \pm 0.4$  EGCG [ $P < .05$ ]) (fold increase). Gene expression levels of inflammatory cytokines, including tumor necrosis factor- $\alpha$  and interleukin-1 $\beta$ , were significantly downregulated in the EGCG group ( $1.82 \pm 0.71$  vs  $0.97 \pm 0.59$  [ $P < .05$ ] and  $3.91 \pm 3.24$  vs  $0.89 \pm 0.59$  [ $P < .05$ ], respectively). On day 7, gene expression levels and gelatinolytic activity of matrix metalloproteinase 9 were significantly lower in the EGCG group ( $1.41 \pm 0.86$  vs  $0.51 \pm 0.42$  [ $P < .05$ ] and  $1.00 \pm 0.17$  vs  $0.29 \pm 0.12$  [ $P < .0001$ ], respectively), whereas gene expression levels of tissue inhibitors of metalloproteinase-1 were significantly higher in the EGCG group ( $0.96 \pm 0.11$  vs  $1.14 \pm 0.09$ ;  $P < .05$ ).

**Conclusions:** EGCG attenuated AAA progression in a rat model by preserving the aortic thickness and elastin content of the medial layer through regeneration of elastin, as mediated by anti-inflammatory effects, and subsequent reduction of matrix metalloproteinase activity. (J Vasc Surg 2017;65:1803-12.)

**Clinical Relevance:** Therapeutic options for abdominal aortic aneurysm (AAA) are currently limited to invasive surgical or endovascular repair. Although advances in diagnosis have allowed physicians to detect smaller AAAs, no pharmacologic treatment directly targeting AAA progression has been found thus far. In the present study, we demonstrated that a green tea polyphenol, epigallocatechin-3-gallate, attenuates AAA progression through anti-inflammatory and elastoregenerative mechanisms in a rat AAA model. Regular green tea consumption might be advantageous for patients with a small AAA or as a prophylactic strategy for AAA.

From the Departments of Cardiovascular Surgery<sup>a</sup> and Cardiovascular Medicine,<sup>b</sup> Kyoto University Graduate School of Medicine.

This work was supported by research grants from the Ministry of Education, Culture, Sports, Science, and Technology, Japan to K.M. (15H04938).

Author conflict of interest: none.

Presented as a poster at the American Heart Association Scientific Sessions 2015, Orlando, Fla, November 7-11, 2015.

Additional material for this article may be found online at [www.jvascsurg.org](http://www.jvascsurg.org).

Correspondence: Kenji Minakata, MD, PhD, Department of Cardiovascular Surgery, Kyoto University Graduate School of Medicine, 54 Kawahara-cho, Shogoin, Sakyo-ku, Kyoto, Japan (e-mail: [minakata@kuhp.kyoto-u.ac.jp](mailto:minakata@kuhp.kyoto-u.ac.jp)).

The editors and reviewers of this article have no relevant financial relationships to disclose per the JVS policy that requires reviewers to decline review of any manuscript for which they may have a conflict of interest.

0741-5214

Copyright © 2016 by the Society for Vascular Surgery. Published by Elsevier Inc. <http://dx.doi.org/10.1016/j.jvs.2016.06.003>

Abdominal aortic aneurysm (AAA) is a life-threatening disease characterized by destruction of aortic structure, which can result in vasodilation and subsequent aneurysm due to continuous exposure to arterial blood pressure. Without treatment, an AAA will eventually rupture, which is a potentially fatal complication for the patient.<sup>1</sup> Although recent advances in disease screening and diagnostics have allowed physicians to detect smaller AAAs,<sup>2</sup> no effective pharmacologic treatment for AAA is currently available, and AAAs with developing size or diameter will eventually require invasive surgical or endovascular therapy.<sup>2,3</sup>

The inflammatory process is considered to be a primary cause of AAA onset and progression. Histologic features of AAA include chronic inflammation of the aorta, inflammatory cell infiltration, reduction of extracellular

matrix, and vascular tissue remodeling.<sup>4</sup> Specifically, reduction and disruption of the elastin component of the medial layer is considered a key factor in AAA progression.<sup>5</sup> Inflammation triggers the reduction of elastin in the medial layer and the progression of aneurysm by activating the secretion of matrix metalloproteinases (MMPs) from inflammatory cells and vascular smooth muscle cells (VSMCs).<sup>4</sup>

Green tea is a popular beverage, historically consumed in the Eastern world, but has recently become popularized globally.<sup>6</sup> Various health-promoting effects of green tea have been proposed, including prevention of cancer and cardiovascular disease,<sup>7,8</sup> anti-inflammatory<sup>9</sup> or anti-oxidative effects,<sup>10</sup> improvement in glycemic control,<sup>11</sup> and reduction of low-density lipoprotein cholesterol,<sup>12</sup> among others. A recent cohort study indicated that the consumption of green tea reduces the risk of death from any cause.<sup>13</sup>

The beneficial effects of green tea have been primarily attributed to polyphenol, a notable bioactive ingredient.<sup>14</sup> Epigallocatechin-3-gallate (EGCG), also known as polyphenolic catechin, exhibits the greatest biological activity among the family of polyphenols<sup>13</sup> and is incorporated in green tea far more abundantly than in any other type of tea.<sup>12</sup> A recent in vitro study that used smooth muscle cells obtained from healthy or aneurysmal rat aorta showed that EGCG exhibited potent regenerative properties for elastin.<sup>15</sup> Considering the previously noted literature on the etiology of AAA, this suggests that green tea may have a promising potential for reducing the risk of AAA. In the present study, we aimed to verify the hypothesis that EGCG attenuates AAA progression, as modulated via anti-inflammatory and elastoregenerative properties, in an experimental rat AAA model.

## METHODS

Detailed methods are provided as the [Appendix](#) (online only).

**Animals.** The study used male Sprague-Dawley rats (400–490 g body weight; CLEA Japan Inc, Tokyo, Japan). All animal procedures were performed in accordance with the guidelines for animal experiments at Kyoto University Graduate School of Medicine and the *Guide for the Care and Use of Laboratory Animals*.<sup>16</sup> We only used male rats because estrogen has been reported to affect the incidence of AAA progression through attenuation of MMP synthesis.<sup>17</sup>

**AAA model.** The experimental AAA model has been described previously.<sup>18</sup> Briefly, animals were anesthetized with isoflurane, and a 10-mm segment of the infrarenal abdominal aorta was exposed through a midline laparotomy. Subsequently, 30 U of porcine pancreatic elastase (135 U/mg; Elastin Products Company, Owensville, Mo) was administered intraluminally

through an SP10 polyethylene catheter (Natsume Seisakusho, Tokyo, Japan) that had been inserted via the right common femoral artery and guided to the aorta. The aorta was wrapped in gauze soaked with 0.5 mol/L CaCl<sub>2</sub> (Sigma-Aldrich, Tokyo, Japan) for 20 minutes, with simultaneous administration of elastase ([Fig 1, A and B](#)).

**Green tea polyphenol solution.** Pure form of EGCG was provided by BioVerde Inc (Kyoto, Japan). EGCG was prepared in a solution at a concentration of 1 mmol/L and given as drinking water, according to the methodology established in our previous report.<sup>19</sup>

**Study groups and EGCG administration.** The rats were randomly divided into a control group (n = 30) and an EGCG group (n = 30). For the EGCG group, a 1.0 mmol/L EGCG solution was administered orally from 2 weeks before the induction of AAAs and continued for another 4 weeks or until euthanasia. Six rats were euthanized for histologic or biochemical analyses on days 0, 2, and 7 after induction and 12 rats on day 28. The control group received tap water over the interval ([Fig 1, C](#)). Fluid consumption was measured daily for each rat.

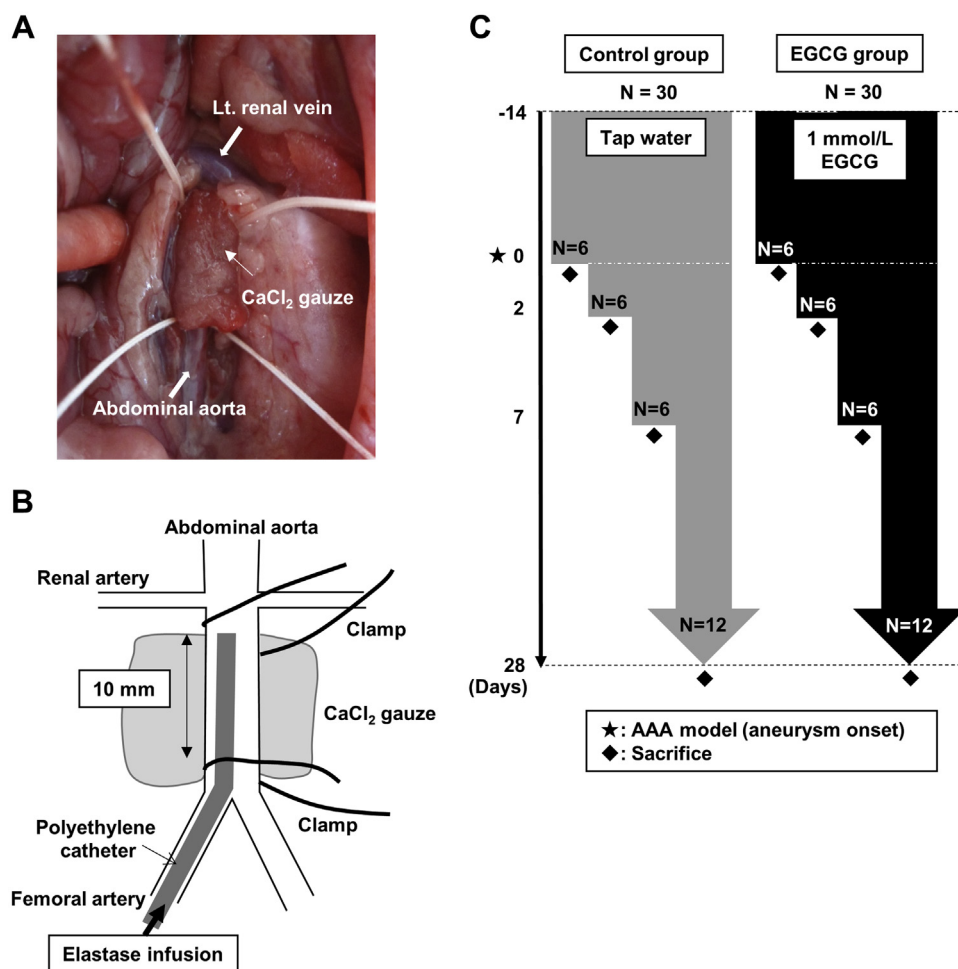
**Measurement of plasma EGCG levels.** Immediately before AAA induction (pre-day 0), a blood sample was obtained from the jugular vein of each rat that had been given EGCG for 2 weeks. Samples were centrifuged at 3000 rpm for 20 minutes. Plasma was collected (50  $\mu$ L), mixed with methanol (150  $\mu$ L), and centrifuged at 13,000 rpm for 4 minutes. After centrifugation, 10  $\mu$ L of the supernatant was applied directly to the liquid chromatography-tandem mass spectrometry system to measure the plasma EGCG concentration.

**Statistical analysis.** Values are presented as mean  $\pm$  standard deviation (SD). Statistical analysis was performed using analysis of variance and Student *t*-tests (GraphPad Prism 6.0; GraphPad Software Inc, La Jolla, Calif). *P* values of  $<.05$  were considered significant.

## RESULTS

Each rat in the EGCG group received an average of 0.09 mL/g body weight/day of EGCG solution, which is equivalent to 0.04 mg/g body weight/day. After drinking the EGCG solution for 2 weeks (pre-day 0), plasma EGCG levels were  $11.2 \pm 7.5$  ng/mL (n = 12). The increase in body weight did not differ significantly between groups, and the general condition of the rats in both groups was stable.

Representative macroscopic images immediately before AAA induction (control group, pre-day 0) and 28 days after AAA induction (day 28) in both groups are shown in [Fig 2, A](#). A difference in the abdominal aortic diameter was observed between groups on pre-day 0 and immediately after (post-day 0) AAA induction. The abdominal aortic diameter in both groups gradually increased after AAA induction, with diameters in the



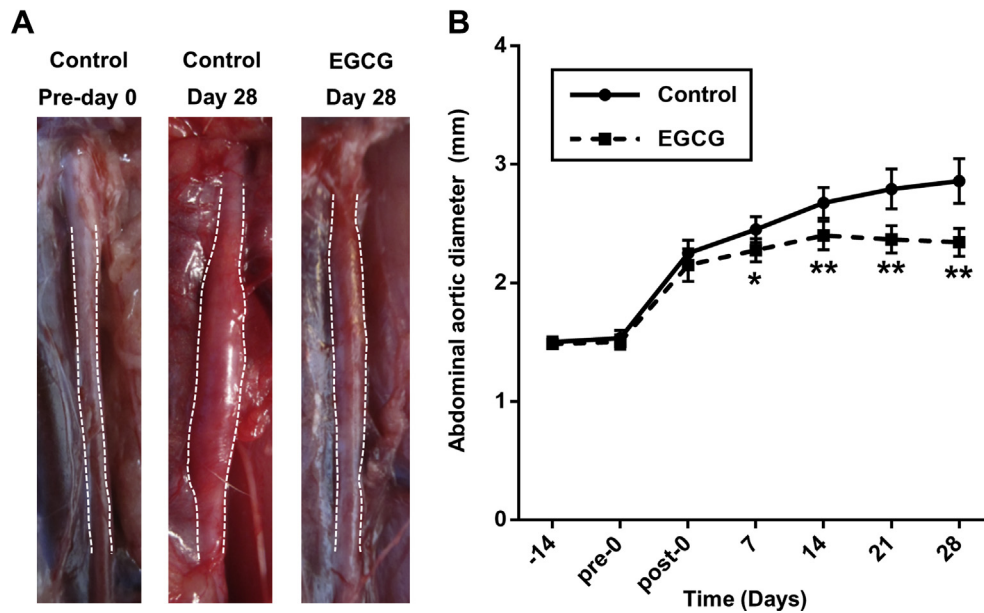
**Fig 1.** The model for induction of abdominal aortic aneurysm (AAA) and the experimental design for in vivo experiments. **A**, A photograph shows the induction of AAA in a rat model. **B**, A schema of the AAA model, which used a combination of intraluminal elastase infusion and extraluminal  $\text{CaCl}_2$  exposure. **C**, Experimental protocol. EGCG, Epigallocatechin-3-gallate.

EGCG group significantly smaller than those in the control group ( $n = 12$  in each group) on days 7 ( $2.5 \pm 0.1$  vs  $2.3 \pm 0.1$  mm;  $P < .01$ ), 14 ( $2.7 \pm 0.1$  vs  $2.4 \pm 0.1$  mm;  $P < .0001$ ), 21 ( $2.8 \pm 0.2$  vs  $2.4 \pm 0.1$  mm;  $P < .0001$ ), and 28 ( $2.9 \pm 0.2$  vs  $2.3 \pm 0.1$  mm;  $P < .0001$ ; Fig 2, B).

We histologically examined the aortic wall thickness in both groups ( $n = 12$  in each group) on day 28 (Fig 3, A and B). Although the total aortic thickness tended to be greater in the EGCG group, no significant difference was observed between groups (control:  $89.4 \pm 28.1$   $\mu\text{m}$ , EGCG:  $110.7 \pm 24.4$   $\mu\text{m}$ ;  $P = .10$ ). The thickness of the intimal layer was slightly less in the EGCG group than in the control group ( $42.4 \pm 15.7$   $\mu\text{m}$  vs  $48.5 \pm 21.9$   $\mu\text{m}$ ;  $P = .37$ ). However, the thickness of the medial layer was significantly greater in the EGCG group than in the control group ( $68.4 \pm 13.6$   $\mu\text{m}$  vs  $46.7 \pm 13.4$   $\mu\text{m}$ ;  $P < .001$ ; Fig 3, B). The elastin content of the medial aortic wall layer was significantly greater in the EGCG group than in the control group on pre-day 0 ( $18.3\% \pm 2.0\%$  vs

$22.2\% \pm 1.8\%$ ,  $n = 6$  in each group;  $P < .01$ ), day 7 ( $6.2\% \pm 1.7\%$  vs  $10.9\% \pm 2.0\%$ ,  $n = 6$  in each group;  $P < .01$ ), and day 28 ( $9.5\% \pm 3.6\%$  vs  $20.3\% \pm 4.6\%$ ,  $n = 12$  in each group;  $P < .0001$ ). The extent of decrease in elastin content from pre-day 0 to day 2 was almost the same in both groups (control: 56.3% decrease, EGCG: 53.2% decrease). Conversely, the extent of increase in elastin content from day 2 to day 28 was higher in the EGCG group (control: 18.8% increase, EGCG: 95.2% increase; Fig 3, C). Transmission electron microscopy of the medial layer in both groups on pre-day 0 indicated a greater proportion of elastin fibers in the EGCG group (Fig 3, D).

As a means of elucidating the mechanism of elastin regeneration mediated by EGCG, we examined the production of tropoelastin (TE) and lysyl oxidase (LOX), which are required for the elastin synthetic process.<sup>15,20,21</sup> Compared with the control group, the EGCG group had significantly higher messenger (m)



**Fig 2.** Macroscopic evaluation of abdominal aortas. **A**, Photographs of the infrarenal abdominal aorta on the day before abdominal aortic aneurysm (AAA) induction (*pre-day 0*) in the control group and on day 28 in the control and epigallocatechin-3-gallate (EGCG) groups. The *dashed lines* were added to aid in the identification of aortic anatomy. **B**, Time course of the abdominal aortic diameter by ultrasound imaging. Values are mean  $\pm$  standard deviation. \* $P < .01$ , \*\* $P < .0001$  vs control group.

RNA expression levels coding TE (control:  $0.59 \pm 0.36$ , EGCG:  $1.24 \pm 0.36$ ,  $n = 6$  in each group;  $P < .05$ ) (fold increase) and LOX (control:  $0.77 \pm 0.45$ , EGCG:  $1.34 \pm 0.41$ ,  $n = 6$  in each group;  $P < .05$ ) (fold increase) on *pre-day 0* (Fig 4, A). Further, we examined expression levels over time after the induction of AAA. The mRNA expression levels coding TE were almost the same between the groups on day 2; however, expression was significantly higher on day 7 in the EGCG group (control:  $0.92 \pm 0.27$ , EGCG:  $1.44 \pm 0.47$ ,  $n = 6$  in each group;  $P < .05$ ; Fig 4, B) (fold increase). The mRNA expression levels coding LOX were significantly higher in the EGCG group than in the control group on day 2 (control:  $0.43 \pm 0.09$ , EGCG:  $0.70 \pm 0.23$ ,  $n = 6$  in each group;  $P < .05$ ) (fold increase), but no significant difference was observed on day 7 (Fig 4, C). Immunostaining for LOX on day 7 revealed a significantly higher proportion of LOX-positive area in the EGCG group (control:  $8.8\% \pm 4.7\%$ , EGCG:  $24.2\% \pm 6.0\%$ ,  $n = 6$  in each group;  $P < .001$ ; Fig 4, D). These results indicate that EGCG may possess regenerative effects for elastin by promoting the elastin synthetic process.

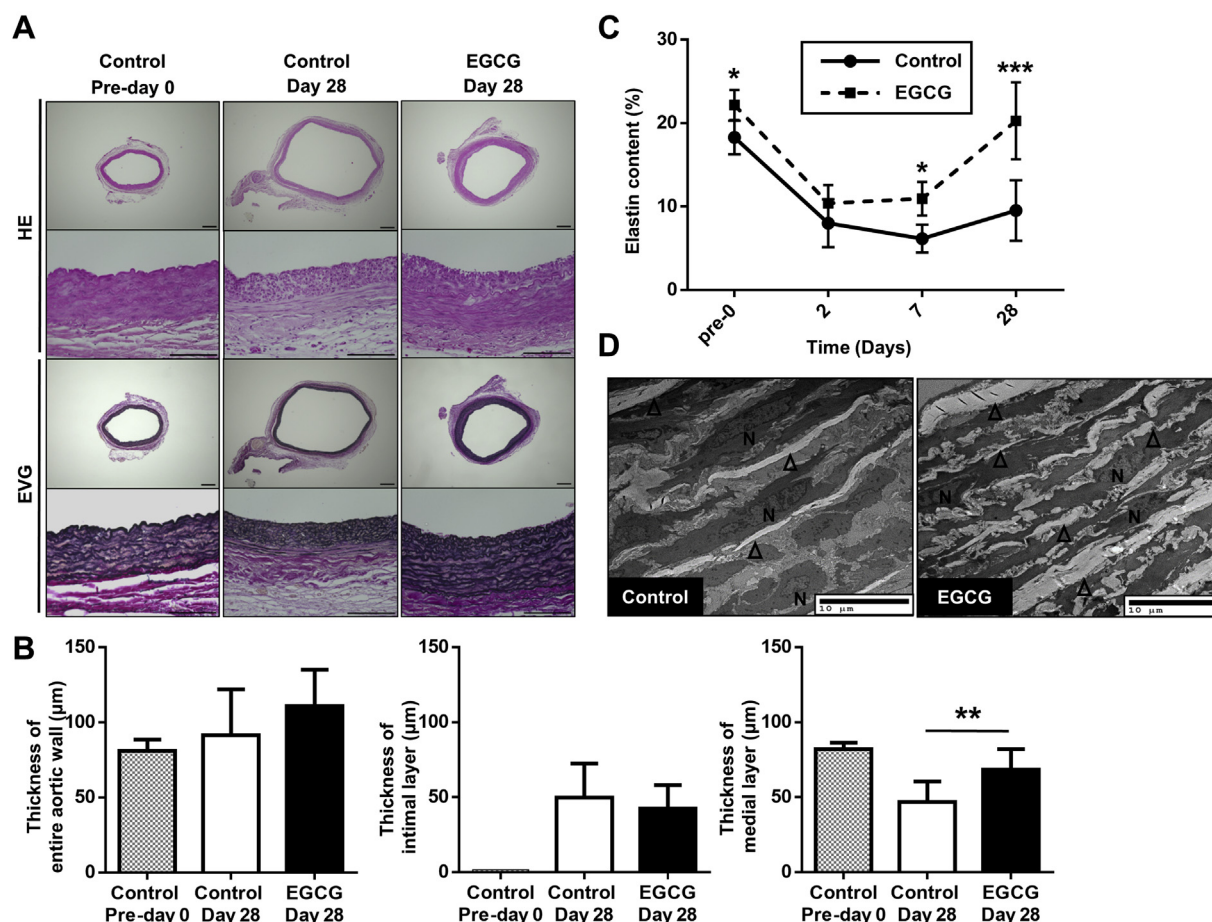
Next, we investigated inflammatory responses and activities of MMPs and tissue inhibitors of metalloproteinases (TIMPs), both of which may affect elastin turnover. On day 2, the mRNA expression levels coding proinflammatory cytokines, tumor necrosis factor- $\alpha$  and interleukin-1 $\beta$ , were significantly downregulated in the EGCG group compared with the control group (tumor necrosis factor- $\alpha$ :  $1.82 \pm 0.71$  for control,  $0.97 \pm 0.59$  for EGCG,  $n = 6$

in each group;  $P < .05$ ; interleukin-1 $\beta$ :  $3.91 \pm 3.24$  for control,  $0.89 \pm 0.59$  for EGCG,  $n = 6$  in each group;  $P < .05$ ; Fig 5, A). On day 7, with cluster of differentiation 68 immunostaining, the number of positive cells observed in the aortic wall was significantly less in the EGCG group (control:  $58.8 \pm 11.9$  cells, EGCG:  $42.2 \pm 6.7$  cells,  $n = 6$  in each group;  $P < .001$ ; Fig 5, B).

On day 7, the mRNA expression levels coding MMP-9 were also significantly downregulated in the EGCG group (control:  $1.41 \pm 0.86$ , EGCG:  $0.51 \pm 0.42$ ,  $n = 6$  in each group;  $P < .05$ ). In contrast, the mRNA expression levels coding TIMP-1 in the EGCG group were significantly upregulated compared with those in the control group (control:  $0.96 \pm 0.11$ , EGCG:  $1.14 \pm 0.09$ ,  $n = 6$  in each group;  $P < .05$ ; Fig 5, C). The gelatinolytic activity of MMP-9 was significantly lower in the EGCG group than in the control group on day 7 (control:  $1.00 \pm 0.17$ , EGCG:  $0.29 \pm 0.12$ ,  $n = 5$  in each group;  $P < .0001$ ). However, the difference in MMP-2 between the groups was not significant (control:  $1.00 \pm 0.14$ , EGCG:  $0.92 \pm 0.16$ ,  $n = 5$  in each group;  $P = .43$ ; Fig 5, D). These results suggest that an anti-inflammatory effect mediated by EGCG attenuates MMP activation, leading to the prevention of elastin degeneration in the aortic medial layer.

Finally, to evaluate potential side effects mediated by EGCG intake, such as stenosis in vessels or hepatotoxic effects,<sup>22</sup> we examined whether EGCG administration resulted in stenosis of the carotid or coronary arteries or in hepatic dysfunction. No stenosis was detected after 6 weeks of treatment, and wall thickness was





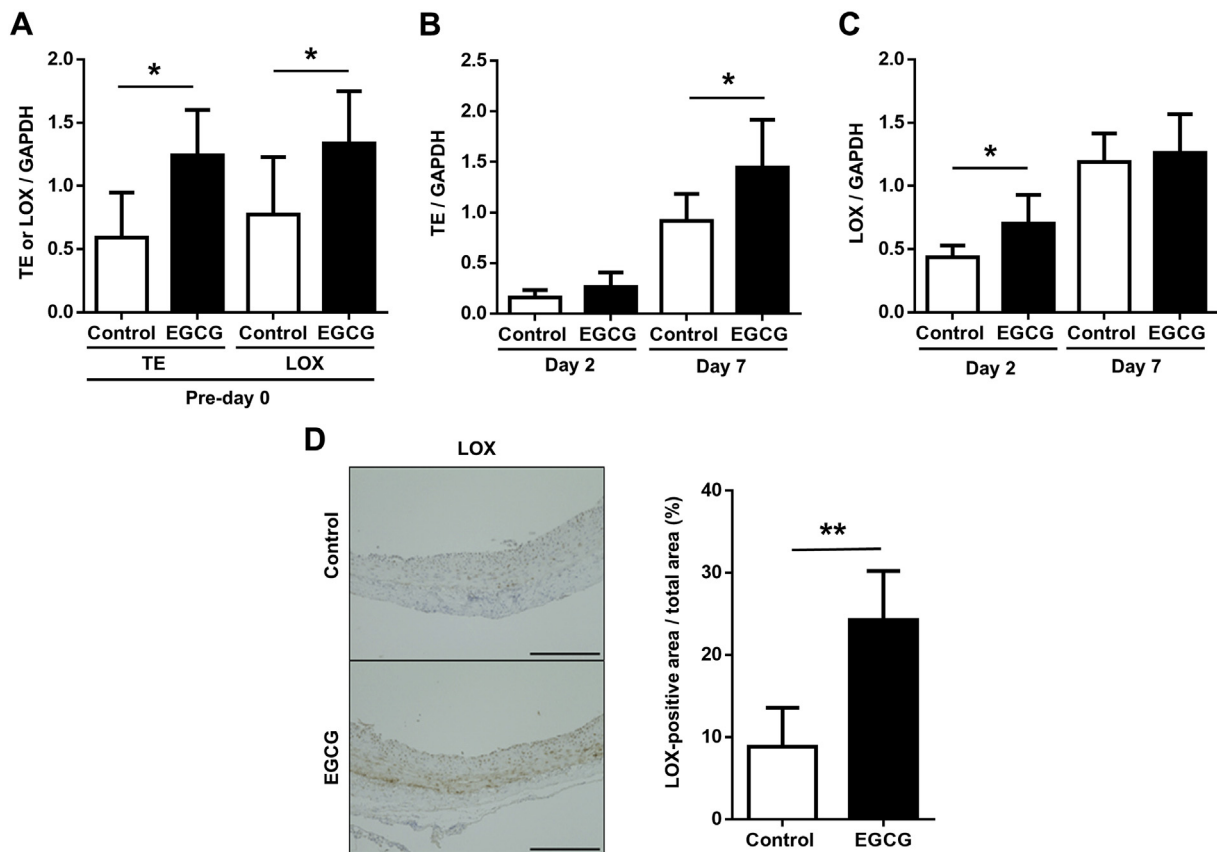
**Fig 3.** Histologic evaluation of the abdominal aorta. **A**, Histologic findings from the abdominal aorta cross-sections on the day before abdominal aortic aneurysm (AAA) induction (pre-day 0) in the control group and on day 28 in the control and epigallocatechin-3-gallate (EGCG) groups, stained with hematoxylin and eosin (HE) for morphologic assessment and elastica van Gieson (EVG) for elastin assessment (upper panels: original magnification  $\times 40$ ; scale bar: 300  $\mu\text{m}$ ; lower panels: original magnification  $\times 400$ ; scale bar: 100  $\mu\text{m}$ ). **B**, Quantitative analysis of the thickness of the entire aortic wall, intimal layer, and medial layer on pre-day 0 in the control group and on day 28 in the control and EGCG groups. **C**, Time course of the elastin content in the medial layer of the abdominal aortic wall. **D**, Representative transmission electron microscopy images on pre-day 0 for the control and EGCG groups. N, Nuclei of vascular smooth muscle cell. Arrowheads: elastic fibers. Scale bar: 10  $\mu\text{m}$ . Values are mean  $\pm$  standard deviation. \* $P < .01$ , \*\* $P < .001$ , \*\*\* $P < .0001$  vs control group.

similar in both groups for the carotid artery (control:  $43.1 \pm 1.8 \mu\text{m}$ , EGCG:  $44.4 \pm 3.5 \mu\text{m}$ ,  $n = 3$  in each group;  $P = .59$ ; Fig 6, A) and the coronary artery (control:  $10.5 \pm 1.2 \mu\text{m}$ , EGCG:  $9.9 \pm 1.2 \mu\text{m}$ ,  $n = 3$  in each group;  $P = .55$ ; Fig 6, B). Serum alanine aminotransferase and bilirubin were also within normal reference ranges in the EGCG group ( $24.5 \pm 2.1 \text{ IU/L}$  and  $0.055 \pm 0.003 \text{ mg/dL}$ , respectively,  $n = 4$ ; Fig 6, C). These results indicate that regular EGCG intake does not result in apparent adverse effects at the doses used in this study.

## DISCUSSION

In the present study, we have shown that oral intake of a potent green tea polyphenol, EGCG, attenuates AAA progression via anti-inflammatory and elastoregenerative mechanisms in a rat AAA model. Inflammatory processes are considered to be a major factor in

the pathophysiology of AAA,<sup>4</sup> and drugs alleviating inflammation, such as statins,<sup>23,24</sup> angiotensin converting enzyme inhibitors,<sup>25,26</sup> and angiotensin II receptor blockers,<sup>27,28</sup> have previously been tested in animal and clinical models.<sup>29</sup> Most of these reports have concluded that the inhibitory mechanisms protecting against AAA development are primarily attributable to protection from the degeneration of medial elastin, as achieved by reductions in inflammatory cell infiltration or reactive oxygen species production. It has been suggested that this protection results from anti-inflammatory or antioxidative effects mediated by the therapeutic reagents in question and the subsequent attenuation of MMP activity.<sup>30-32</sup> In the present study, we observed that the aortic elastin content degraded within a few days after the induction of AAA to a degree that was the same irrespective of EGCG administration. We further confirmed a dramatic increase in the



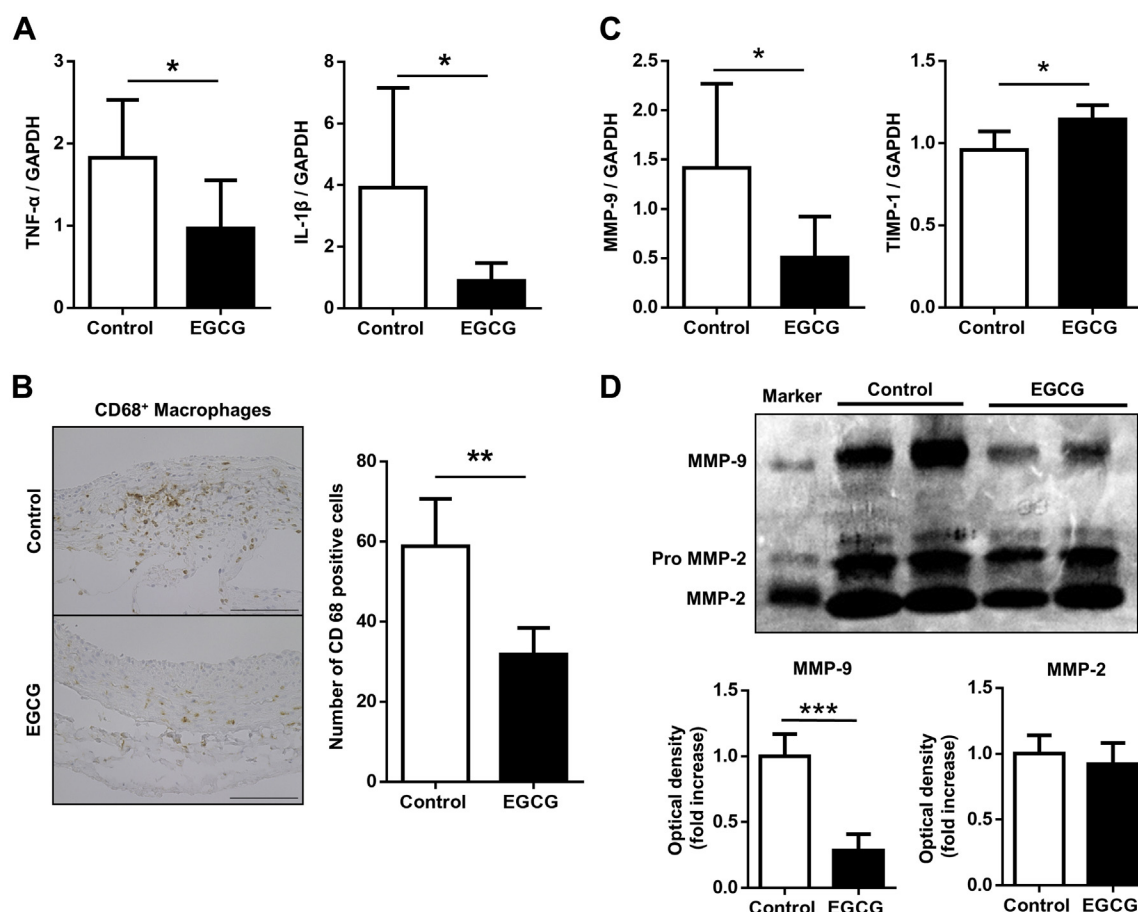
**Fig 4.** Evaluation of elastin synthesis and regeneration in the abdominal aorta. **A**, Messenger RNA (mRNA) expression levels coding tropoelastin (TE) and lysyl oxidase (LOX) in the aortic wall on the day before abdominal aortic aneurysm (AAA) induction (pre-day 0) in the control and the epigallocatechin-3-gallate (EGCG) groups. mRNA expression levels coding **(B)** TE and **(C)** LOX in the aortic wall on days 2 and 7 in the control and the EGCG groups. **D, Left:** Immunohistochemical staining on day 7 for LOX in the aortic tissue (original magnification  $\times 400$ ; scale bar, 100  $\mu\text{m}$ ). **Right:** Quantification of LOX-positive area. Values are mean  $\pm$  standard deviation. GAPDH, Glyceraldehyde-3-phosphate dehydrogenase \* $P < .05$ , \*\* $P < .001$  vs control group.

medial elastin component over time in rats receiving EGCG, in contrast to the limited degree of elastin recovery in rats without EGCG, indicating a potential elastoregenerative effect mediated by EGCG. Such an effect has not previously been reported in the literature of in vivo experiments, irrespective of the reagent.

Elastin is synthesized by TE, a soluble monomeric precursor with a molecular mass of 62 to 75 kDa, which is secreted from VSMCs or fibroblasts. TE assembles through coacervation to form an insoluble polymeric structure, referred to as elastic fiber, which is the primary component of the extracellular matrix in the aortic medial layer. In this process, LOX catalyzes a key step in the cross-linking and stabilization of elastin in the vascular walls. We demonstrated an increase in mRNA expression levels of TE and LOX, both of which are required for elastin synthesis, and further confirmed the increase of LOX at a molecular level in the EGCG group. In contrast, Shinha et al<sup>15</sup> previously reported that the addition of EGCG did not influence cellular TE

production in healthy VSMCs in vitro. Sommer et al<sup>33</sup> showed that fibroblasts stimulated by transforming growth factor- $\beta 1$  promote TE production; therefore, it is possible that elastogenic cells other than VSMCs, such as fibroblasts, existing in vivo, might be a potential source of TE production in this study. It is our future work to elucidate how cell types other than VSMCs contribute to elastin production or stabilization, or both, with an in vitro culture condition.

Activated VSMCs and infiltrated inflammatory cells produce MMPs, specifically MMP-2 and MMP-9, which play important roles in AAA development. Tanaka et al<sup>18</sup> reported that rat AAA induced by elastase and  $\text{CaCl}_2$ -treated aortas exhibited markedly increased MMP-9 activity. In this study, EGCG administration significantly attenuated the mRNA expression level and the proteolytic activity of MMP-9 in the aortic tissue. Downregulation of TIMPs has been reported to result in proteolytic extracellular matrix degradation, a process that contributes to aneurysmal formation.<sup>31,32</sup> In the present



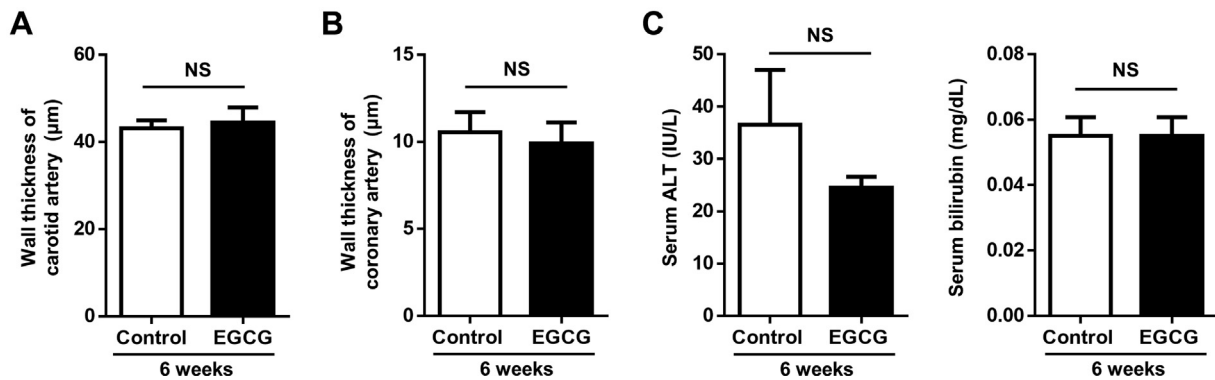
**Fig 5.** Evaluation of the inflammatory response in abdominal aortas. **A**, Messenger RNA (mRNA) expression levels coding tumor necrosis factor (TNF)- $\alpha$  and interleukin (IL)-1 $\beta$  on day 2 in the control and the epigallocatechin-3-gallate (EGCG) groups. **B**, **Left**: Immunohistochemical staining of cluster of differentiation (CD) 68-positive cells for macrophages in the aortic tissue on day 7 (original magnification  $\times 400$ ; scale bar, 100  $\mu$ m). **Right**: Quantification of CD68-positive cells. **C**, mRNA expression of matrix metalloproteinase (MMP)-9 and tissue inhibitors of metalloproteinase (TIMP)-1 on day 7 in the control and the EGCG groups. **D**, **Top**: Gelatin zymography on day 7. **Bottom**: Densitometric analysis of MMP-9 and MMP-2 abundance. Values are mean  $\pm$  standard deviation. \* $P < .05$ , \*\* $P < .001$ , \*\*\* $P < .0001$  vs control group.

study, mRNA expression levels of TIMP-1 in the EGCG group were also significantly increased compared with those in the control group. In addition to an elastoregenerative potential, we demonstrated that EGCG might attenuate the degradation of extracellular matrix proteins, including elastin. Therefore, we propose that the attenuation of elastin degeneration through suppression of the inflammation process, in addition to the regeneration of elastin, is responsible for increasing the proportion of elastin in the medial aortic layer and, consequently, reinforcing the aortic structure and mitigating the progression of AAA (Fig 7).

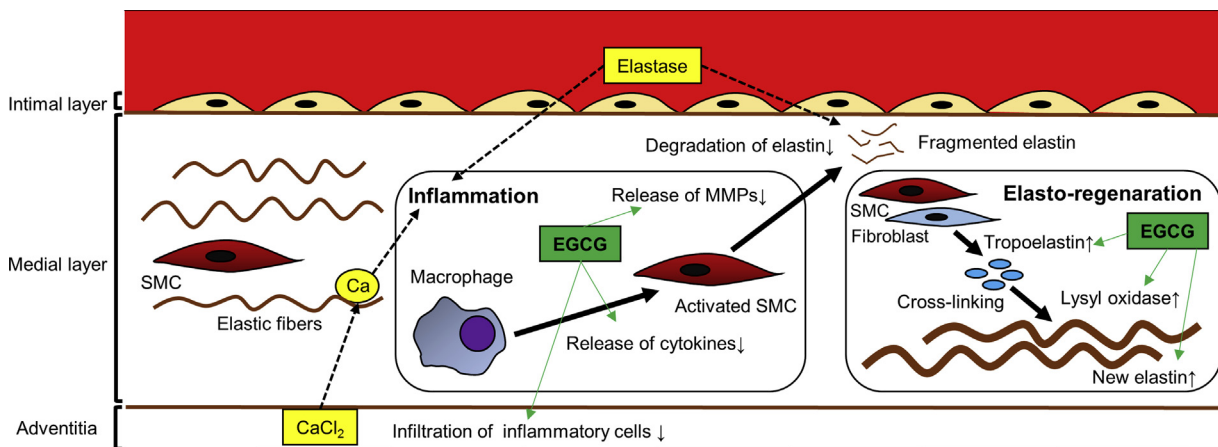
The present study may pose an epidemiologically intriguing attempt to prevent AAA progression with daily consumption of green tea before AAA onset. The Japanese population has been reported to have the longest lifespan in the world,<sup>34</sup> and studies have reported that as much as 80% of this population

consume green tea daily.<sup>35</sup> Saito et al<sup>13</sup> reported that 5 cups of green tea per day, over an 18.7-year follow-up period, reduced mortality from any cause to 13% in men and 17% in women. Another recent study investigated the consumption of alcoholic beverages that include polyphenols, such as wine and beer, finding an attenuated AAA risk.<sup>36</sup> This may provide further evidence for the potential benefits of green tea in the prevention of AAA progression. The amount of EGCG consumption of the rats in the present study was almost equivalent with 6 to 9 L/d of green tea consumption in adult human. However, it would be possible to expect same level of effect with a little lower amount of green tea consumption because green tea includes various catechins besides EGCG.

This study has several limitations. First, the rat model of elastase and CaCl<sub>2</sub>-induced AAA that was used in our study is pathologically different from human AAAs,



**Fig 6.** Evaluation of side effects resulting from epigallocatechin-3-gallate (EGCG) intake after 6 weeks of administration. Quantitative analysis of wall thickness of the (A) carotid artery and (B) coronary artery. C, Serum levels of alanine transaminase (ALT) and bilirubin. NS, Not significant. Values are mean  $\pm$  standard deviation.



**Fig 7.** Proposed mechanisms for abdominal aortic aneurysm (AAA) prevention with epigallocatechin-3-gallate (EGCG) administration. MMP, Matrix metalloproteinase; SMC, smooth muscle cell.

which typically exhibit atherosclerosis and intramural thrombosis. It is our future work to use atherogenic models such as diabetic or hyperlipidemia rats. In the present study, we observed rapid progression of AAA during the first 7 days after administration of elastase, which is clearly different from the AAA progression pattern in humans.

Second, whether the EGCG dose used in this study was appropriate is unclear, because the pharmacokinetics of EGCG might differ in humans. Although EGCG levels in the control group were not tested on pre-day 0, several previous reports indicated that EGCG was not detected in plasma samples collected before tea administration in humans or in rats that received the diet without EGCG, and we considered the EGCG concentration in control rats as undetectable.<sup>37,38</sup> We selected the EGCG dose based on our previous report, which showed a cardioprotective effect in Langendorff-perfused isolated rat hearts that were subjected to ischemia-reperfusion injury.<sup>19</sup> In the study, plasma EGCG levels were shown to gradually increase

in the first 2 weeks and then reach a plateau in rats given EGCG solution.<sup>39</sup>

Despite the lack of clarity regarding the clinically relevant dosage, the dosage of EGCG that was used in this study did not show adverse effects with respect to stenotic lesions in carotid or coronary arteries or to hepatic dysfunction. Further investigation is required regarding the optimal dosage that is appropriate for daily consumption of EGCG.

Finally, whether EGCG can attenuate AAA progression when administrated after the onset of AAA is unknown, and investigation of this point will be the focus of future studies.

## CONCLUSIONS

Oral administration of EGCG, a major component of green tea polyphenols, attenuated AAA progression via the regeneration of elastin and the prevention of elastin degradation, as obtained through anti-inflammatory activity in the medial layer of rat AAA models. Daily green



tea intake should be considered as a potential novel preventive strategy for AAA.

We thank Dr Yasuaki Nakagawa, Dr Kazuo Matsubara, Dr Tomohiro Omura, Dr Shunsaku Nakagawa, Shuichi Miyake, Keiko Okamoto-Furuta, and Haruyasu Kohda (Kyoto University) for technical support. We also thank Dr Suong-Hyu Hyon (Center for Fiber and Textile Science, Kyoto Institute of Technology) and Yuki Gen (BioVerde, Inc, Kyoto, Japan) for providing EGCG. This manuscript was reviewed by Editage ([www.editage.jp](http://www.editage.jp)) for English language editing.

## AUTHOR CONTRIBUTIONS

Conception and design: SS, KM, KY, KK, RS

Analysis and interpretation: SS, KM, HM, TI

Data collection: SS, SH

Writing the article: SS, KM, HM

Critical revision of the article: KM, HM

Final approval of the article: SS, KM, HM, SH, KY, KK, TI, RS

Statistical analysis: SS, HM

Obtained funding: KM

Overall responsibility: KM

## REFERENCES

- Kent KC, Zwolak RM, Egorova NN, Riles TS, Manganaro A, Moskowitz AJ, et al. Analysis of risk factors for abdominal aortic aneurysm in a cohort of more than 3 million individuals. *J Vasc Surg* 2010;52:539-48.
- Moll FL, Powell JT, Fraedrich G, Verzini F, Haulon S, Waltham M, et al. Management of abdominal aortic aneurysms clinical practice guidelines of the European Society for Vascular Surgery. *Eur J Vasc Endovasc Surg* 2011;41:S1-58.
- The United Kingdom EVER Trial Investigators, Greenhalgh RM, Brown LC, Powell JT, Thompson SG, Epstein D, Sculpher MJ. Endovascular versus open repair of abdominal aortic aneurysm. *N Engl J Med* 2010;362:1863-71.
- Ailawadi G, Eliason JL, Upchurch GR Jr. Current concepts in the pathogenesis of abdominal aortic aneurysm. *J Vasc Surg* 2003;38:584-8.
- Campa JS, Greenhalgh RM, Powell JT. Elastin degradation in abdominal aortic aneurysms. *Atherosclerosis* 1987;65:13-21.
- Cooper R, Morr  DJ, Morr  DM. Medicinal benefits of green tea: Part I. Review of noncancer health benefits. *J Altern Complement Med* 2005;11:521-8.
- Kuriyama S, Shimazu T, Ohmori K, Kikuchi N, Nakaya N, Nishino Y, et al. Green tea consumption and mortality due to cardiovascular disease, cancer, and all causes in Japan: the Ohsaki Study. *JAMA* 2006;296:1255-65.
- Tang J, Zheng JS, Fang L, Jin Y, Cai W, Li D. Tea consumption and mortality of all cancers, CVD and all causes: a meta-analysis of eighteen prospective cohort studies. *Br J Nutr* 2015;114:673-83.
- Cao Y, Bao S, Yang W, Zhang J, Li L, Shan Z, et al. Epigallocatechin gallate prevents inflammation by reducing macrophage infiltration and inhibiting tumor necrosis factor- $\alpha$  signaling in the pancreas of rats on a high-fat diet. *Nutr Res* 2014;34:1066-74.
- Tipoe GL, Leung TM, Hung MW, Fung ML. Green tea polyphenols as an anti-oxidant and anti-inflammatory agent for cardiovascular protection. *Cardiovasc Hematol Disord Drug Targets* 2007;7:135-44.
- Zheng XX, Xu YL, Li SH, Hui R, Wu YJ, Huang XH. Effects of green tea catechins with or without caffeine on glycemic control in adults: a meta-analysis of randomized controlled trials. *Am J Clin Nutr* 2013;97:750-62.
- Raederstorff DG, Schlachter MF, Elste V, Weber P. Effect of EGCG on lipid absorption and plasma lipid levels in rats. *J Nutr Biochem* 2003;14:326-32.
- Saito E, Inoue M, Sawada N, Shimazu T, Yamaji T, Iwasaki M, et al. Association of green tea consumption with mortality due to all causes and major causes of death in a Japanese population: the Japan Public Health Center-based Prospective Study (JPHC Study). *Ann Epidemiol* 2015;25:512-8.e3.
- Chacko SM, Thambi PT, Kuttan R, Nishigaki I. Beneficial effects of green tea: a literature review. *Chin Med* 2010;5:13.
- Sinha A, Nosoudi N, Vyavahare N. Elasto-regenerative properties of polyphenols. *Biochem Biophys Res Commun* 2014;444:205-11.
- National Research Council (US) Institute for Laboratory Animal Research. Guide for the care and use of laboratory animals. Washington, DC: The National Academies Press; 1996.
- Wu XF, Zhang J, Paskauskas S, Xin SJ, Duan ZQ. The role of estrogen in the formation of experimental abdominal aortic aneurysm. *Am J Surg* 2009;197:49-54.
- Tanaka A, Hasegawa T, Chen Z, Okita Y, Okada K. A novel rat model of abdominal aortic aneurysm using a combination of intraluminal elastase infusion and extraluminal calcium chloride exposure. *J Vasc Surg* 2009;50:1423-32.
- Yanagi S, Matsumura K, Marui A, Morishima M, Hyon SH, Ikeda T, et al. Oral pretreatment with a green tea polyphenol for cardioprotection against ischemia-reperfusion injury in an isolated rat heart model. *J Thorac Cardiovasc Surg* 2011;141:511-7.
- Xiong J, Wang SM, Chen LH, Lin Y, Zhu YF, Ye CS. Elastic fibers reconstructed using adenovirus-mediated expression of tropoelastin and tested in the elastase model of abdominal aortic aneurysm in rats. *J Vasc Surg* 2008;48:965-73.
- Nuthakki VK, Fleser PS, Malinzak LE, Seymour ML, Callahan RE, Bendick PJ, et al. Lysyl oxidase expression in a rat model of arterial balloon injury. *J Vasc Surg* 2004;40:123-9.
- Lambert JD, Kennett MJ, Sang S, Reuhl KR, Ju J, Yang CS. Hepatotoxicity of high oral dose (-) epigallocatechin-gallate in mice. *Food Chem Toxicol* 2010;48:409-16.
- Kalyanasundaram A, Elmore JR, Manazer JR, Golden A, Franklin DP, Galt SW, et al. Simvastatin suppresses experimental aortic aneurysm expansion. *J Vasc Surg* 2006;43:117-24.
- Shiraya S, Miyake T, Aoki M, Fujiwara Y, Ohgi S, Nishimura M, et al. Inhibition of development of experimental aortic abdominal aneurysm in rat model by atorvastatin through inhibition of macrophage migration. *Atherosclerosis* 2009;202:34-40.
- Liao S, Miralles M, Kelley BJ, Curci JA, Borhani M, Thompson RW. Suppression of experimental abdominal aortic aneurysms in the rat by treatment with angiotensin-converting enzyme inhibitors. *J Vasc Surg* 2001;33:1057-64.
- Xiong F, Zhao J, Zeng G, Huang B, Yuan D, Yang Y. Inhibition of AAA in a rat model by treatment with ACEI perindopril. *J Surg Res* 2014;189:166-73.
- Fujiwara Y, Shiraya S, Miyake T, Yamakawa S, Aoki M, Makino H, et al. Inhibition of experimental abdominal aortic aneurysm in a rat model by the angiotensin receptor blocker valsartan. *Int J Mol Med* 2008;22:703-8.
- Iida Y, Xu B, Schultz GM, Chow V, White JJ, Sulaimon S, et al. Efficacy and mechanism of angiotensin II receptor blocker treatment in experimental abdominal aortic aneurysms. *PLoS One* 2012;7:e49642.
- Motoki T, Kurobe H, Hirata Y, Nakayama T, Kinoshita H, Rocco KA, et al. PPAR- $\gamma$  agonist attenuates inflammation in

- aortic aneurysm patients. *Gen Thorac Cardiovasc Surg* 2015;63:565-71.
30. Morimoto K, Hasegawa T, Tanaka A, Wulan B, Yu J, Morimoto N, et al. Free-radical scavenger edaravone inhibits both formation and development of abdominal aortic aneurysm in rats. *J Vasc Surg* 2012;55:1749-58.
  31. Shang T, Liu Z, Liu CJ. Antioxidant vitamin C attenuates experimental abdominal aortic aneurysm development in an elastase-induced rat model. *J Surg Res* 2014;188:316-25.
  32. Tanaka A, Hasegawa T, Morimoto K, Bao W, Yu J, Okita Y, et al. Controlled release of ascorbic acid from gelatin hydrogel attenuates abdominal aortic aneurysm formation in rat experimental abdominal aortic aneurysm model. *J Vasc Surg* 2014;60:749-58.
  33. Sommer N, Sattler M, Weise JM, Wenck H, Gallinat S, Fischer F. A tissue-engineered human dermal construct utilizing fibroblasts and transforming growth factor  $\beta$ 1 to promote elastogenesis. *Biotechnol J* 2013;8:317-26.
  34. World Health Organization. World health statistics 2015. Luxembourg: World Health Organization; 2015. p. 43-53.
  35. Sasazuki S, Inoue M, Hanaoka T, Yamamoto S, Sobue T, Tsugane S. Green tea consumption and subsequent risk of gastric cancer by subsite: the JPHC Study. *Cancer Causes Control* 2004;15:483-91.
  36. Stackelberg O, Björck M, Larsson SC, Orsini N, Wolk A. Alcohol consumption, specific alcoholic beverages, and abdominal aortic aneurysm. *Circulation* 2014;130:646-52.
  37. Lee MJ, Maliakal P, Chen L, Meng X, Bondoc FY, Prabhu S, et al. Pharmacokinetics of tea catechins after ingestion of green tea and (–)-epigallocatechin-3-gallate by humans: formation of different metabolites and individual variability. *Cancer Epidemiol Biomarkers Prev* 2002;11:1025-32.
  38. Ferri P, Angelino D, Gennari L, Benedetti S, Ambrogini P, Del Grande P, et al. Enhancement of flavonoid ability to cross the blood-brain barrier of rats by co-administration with  $\alpha$ -tocopherol. *Food Funct* 2015;6:394-400.
  39. Kim S, Lee MJ, Hong J, Li C, Smith TJ, Yang GY, et al. Plasma and tissue levels of tea catechins in rats and mice during chronic consumption of green tea polyphenols. *Nutr Cancer* 2000;37:41-8.

Submitted Mar 22, 2016; accepted Jun 5, 2016.

*Additional material for this article may be found online at [www.jvascsurg.org](http://www.jvascsurg.org).*

## APPENDIX (online only).

### Methods

**Animals.** The study used male Sprague-Dawley rats (400–490 g body weight; CLEA Japan Inc, Tokyo, Japan). All animal procedures were performed in accordance with the guidelines for animal experiments at Kyoto University Graduate School of Medicine and the *Guide for the Care and Use of Laboratory Animals*.<sup>1</sup> We only used male rats because estrogen has been reported to affect to the incidence of AAA progression through attenuation of metalloproteinase (MMP) synthesis.<sup>2</sup>

**AAA model.** The experimental AAA model has been described previously.<sup>3</sup> Briefly, animals were anesthetized with isoflurane, and a 10-mm segment of the infrarenal abdominal aorta was exposed through a midline laparotomy. Subsequently, 30 U of porcine pancreatic elastase (135 U/mg; Elastin Products Company, Owensville, Mo) was administered intraluminally through an SP10 polyethylene catheter (Natsume Seisakusho, Tokyo, Japan) that had been inserted via the right common femoral artery and guided to the aorta. The aorta was wrapped in gauze soaked with 0.5 mol CaCl<sub>2</sub> (Sigma-Aldrich, Tokyo, Japan) for 20 minutes, with simultaneous administration of elastase. The abdominal incision was closed in layers, and the rats were allowed to recover from anesthesia (Fig 1, A and B).

**Green tea polyphenol solution.** Green tea extract, in the form of pure epigallocatechin-3-gallate (EGCG), was provided by BioVerde Inc (Kyoto, Japan). EGCG was prepared in a solution at a concentration of 1 mmol/L and given as drinking water, according to the methodology established in our previous report.<sup>4</sup>

**Study groups and EGCG administration.** The rats were randomly divided into the control group (n = 30) and the EGCG group (n = 30). For the EGCG group, a 1.0 mmol/L EGCG solution was administered orally from 2 weeks before the induction of AAAs and continued for another 4 weeks or until euthanasia. Six rats each were euthanized for histologic or biochemical analyses on days 0, 2, and 7 after induction and 12 rats on day 28. The control group received tap water over the same interval (Fig 1, C). Fluid consumption was measured daily for each rat.

**Measurement of plasma EGCG levels.** Immediately before AAA induction (pre-day 0), a blood sample was obtained from the jugular vein of each rat that had been given EGCG for 2 weeks. Samples were centrifuged at 3000 rpm for 20 minutes. Plasma was collected (50  $\mu$ L), mixed with methanol (150  $\mu$ L) and centrifuged at 13,000 rpm for 4 minutes. After centrifugation, 10  $\mu$ L of the supernatant was applied directly to the liquid chromatography-tandem mass spectrometry (LC-MS/MS) system for measurement of the plasma EGCG concentration. The LC-MS/MS system assay was performed using an LC system consisting of a Prominence series chromatograph (Shimadzu, Kyoto, Japan) coupled to an

API 4000 triple-quadrupole MS/MS system (AB SCIEX, Foster City, Calif). Chromatographic separation was carried out on COSMOSIL 5C18-MS-II (Nacalai Tesque, Kyoto, Japan). The MS/MS analysis was performed using an electrospray ionization source in the negative mode.<sup>5</sup> Detection was carried out by monitoring the ion transition of EGCG from m/z 457 to 169.

### Measurements of the abdominal aortic diameter.

With the rats under anesthesia, the maximum infrarenal abdominal aortic diameters were measured using an ultrasound apparatus (Vivid7; GE Healthcare, Buckinghamshire, United Kingdom). Measurements were taken when the solution was first administered (–14 days), immediately before AAA induction, and on days 0, 7, 14, 21 and 28 after AAA induction (n = 12).

**Histologic analysis.** Paraffin-embedded 5- $\mu$ m-thick sections were stained with hematoxylin and eosin and elastica van Gieson (EVG) for identification of elastin. Images were photographed using an all-in-one digital microscope (BZ-9000; KEYENCE Co, Osaka, Japan), and assessed using the BZ-X Analyzer (KEYENCE) software. The total thicknesses of the aortic wall, the thicknesses of the intimal and medial layers, and the wall thicknesses of the carotid and the coronary arteries (middle portion of circumflex branch) were measured at eight points of the cross-sectional vessel walls in the EVG-stained sections. Average thickness values were then calculated from the eight measurements. Elastin-positive area was measured using the EVG-stained cross-sectional aortic wall to highlight internal elastic lamina and external elastic lamina,<sup>6</sup> and the percentage of elastin content in the medial layer was calculated automatically using the BZ-X Analyzer.

**Transmission electron microscopy.** Samples of the abdominal aorta immediately before AAA induction (pre-day 0) were fixed at 4°C overnight with 4% paraformaldehyde and 2% glutaraldehyde in 0.1 mol/L phosphate buffer (pH 7.4). Sections were postfixated with 1% osmium tetroxide in 0.1 mol/L phosphate buffer, dehydrate ethanol series, and then embedded in epoxy-resin Luveak-812 (Nacalai Tesque, Kyoto, Japan). The tissue samples were cut into ultra-thin sections (70 nm) on an ultramicrotome (EM UC6; Leica, Heidelberg, Germany) and observed under an electron microscope (H-7650; Hitachi, Tokyo, Japan).

### Immunohistochemistry and quantitative analysis.

Immunohistochemical staining was performed on paraffin-embedded sections on day 7 with an antibody specific for lysyl oxidase (LOX) (ab31238; Abcam, Cambridge, United Kingdom), and cluster of differentiation (CD) 68 for macrophages (MAB1435; Millipore, Billerica, Mass). Briefly, deparaffinized sections were incubated overnight at 4°C with a primary antibody for LOX (1:300) and CD68 (1:500) and then incubated at room

temperature for 45 minutes in a solution with an anti-mouse immunoglobulin G secondary antibody (Nichirei, Tokyo, Japan). LOX-positive areas in the aortic wall cross section were measured using the BZ-X Analyzer software. The number of CD68-positive cells was calculated as the average number of positive cells, per view, from at least six randomly selected views in each specimen.

**Quantitative real-time polymerase chain reaction.** Total RNA was isolated from frozen abdominal aorta tissue using an RNeasy mini kit (Qiagen, Hilden, Germany). The RNA was reverse-transcribed into complementary DNA using the Invitrogen SuperScript III First-Standard Synthesis SuperMix for quantitative real-time polymerase chain reaction (PCR; Life Technologies, Carlsbad, Calif), in accordance with manufacturer's instructions. Gene-specific primers for rat matrix metalloproteinase (MMP)-9 (Taqman Gene Expression Assays, *Mmp9*; Rn00579162\_m1), tissue inhibitors of metalloproteinase (TIMP)-1 (Taqman, *Timp*; Rn01430873\_g1), tumor necrosis factor (TNF)- $\alpha$  (Taqman, *Tnf*; Rn01525859\_g1), interleukin (IL)-1 $\beta$  (Taqman, *Il1b*; Rn01410330\_m1), LOX (Taqman, *Lox*; Rn01491829\_m1), tropoelastin (TE; Taqman, *Eln*; Rn01499782\_m1), and glyceraldehyde-3-phosphate dehydrogenase (GAPDH; Taqman, *Gapdh*; Rn01775763\_g1) were purchased from Applied Biosystems (Foster City, Calif). Quantitative real-time PCR was performed using the StepOnePlus Real Time PCR System with Taqman Fast Advanced PCR Master Mix (Applied Biosystems). Expression levels for each messenger RNA were normalized to the messenger RNA level of the house-keeping gene (GAPDH).

**Gelatin zymography.** To determine the gelatinolytic activity of MMP-9, a gelatin zymography kit (Cosmo Bio Co, Tokyo, Japan) was used according to the manufacturer's instructions. In brief, an aortic specimen was homogenized in lysis buffer containing protease inhibitors. After centrifugation, the supernatant was collected, and the protein concentration was estimated using the Bio-Rad Protein Assay (Bio-Rad Laboratories, Hercules, Calif), based on the method established by Bradford.<sup>7</sup> Aliquots of the lysate containing 30  $\mu$ g protein

were applied in each lane of electrophoresis, and densitometric analysis of the lytic bands was performed by ImageQuant TL (GE Healthcare).

**Quantification of biochemical makers.** Just before the animals were euthanized, blood was withdrawn from the inferior vena cava. Serum was prepared from the blood by immediate centrifugation at 3000 rpm for 20 minutes at 4°C. Alanine aminotransferase and bilirubin were measured (SRL Inc, Tokyo, Japan) and used as the biochemical markers of hepatotoxicity.

**Statistical analysis.** Values are presented as mean  $\pm$  standard deviation. Statistical analysis was performed using analysis of variance and Student *t*-tests (GraphPad Prism 6.0 software; GraphPad Software, Inc, San Diego, Calif). *P* values < .05 were considered significant.

## REFERENCES

1. National Research Council (US) Institute for Laboratory Animal Research. Guide for the care and use of laboratory animals. Washington, DC: The National Academies Press; 1996.
2. Wu XF, Zhang J, Paskauskas S, Xin SJ, Duan ZQ. The role of estrogen in the formation of experimental abdominal aortic aneurysm. *Am J Surg* 2009;197:49-54.
3. Tanaka A, Hasegawa T, Chen Z, Okita Y, Okada K. A novel rat model of abdominal aortic aneurysm using a combination of intraluminal elastase infusion and extraluminal calcium chloride exposure. *J Vasc Surg* 2009;50:1423-32.
4. Yanagi S, Matsumura K, Marui A, Morishima M, Hyon SH, Ikeda T, et al. Oral pretreatment with a green tea polyphenol for cardioprotection against ischemia-reperfusion injury in an isolated rat heart model. *J Thorac Cardiovasc Surg* 2011;141:511-7.
5. Kikuchi O, Ohashi S, Nakai Y, Nakagawa S, Matsuoka K, Kobunai T, et al. Novel 5-fluorouracil-resistant human esophageal squamous cell carcinoma cells with dihydropyrimidine dehydrogenase overexpression. *Am J Cancer Res* 2015;5:2431-40.
6. Morimoto K, Hasegawa T, Tanaka A, Wulan B, Yu J, Morimoto N, et al. Free-radical scavenger edaravone inhibits both formation and development of abdominal aortic aneurysm in rats. *J Vasc Surg* 2012;55:1749-58.
7. Bradford MM. A rapid and sensitive method for the quantification of microgram quantities of protein utilizing the principle of protein-dye binding. *Anal Biochem* 1976;72:248-54.