Adjunct endovascular interventions in carotid body tumors

Konstantinos P. Economopoulos, MD, PhD,[a,b] **Aspasia Tzani, MS,**[b] and **Thomas Reifsnyder, MD,**[c] *Boston, Mass; Athens, Greece; and Baltimore, Md*

Objective: **Most patients presenting with carotid body tumors (CBTs) seek medical attention when tumors have grown to exceed Shamblin I stage, rendering surgery a challenging undertaking and the associated morbidity a continuing threat to the clinical outcome. This study examined the availability, applicability, and overall clinical efficacy of adjunct endovascular interventions performed alongside CBT surgery and their potential in clinical decision making and clinical practice.**
Methods: **Studies reporting the feasibility, applicability, and clinical efficacy of adjunct endovascular interventions in the surgical management of CBTs were thoroughly searched using the Medline database from January 1967 to August 2013.**
Results: **There were no randomized studies on the efficacy of endovascular interventions in CBT surgery. Sixty studies met our inclusion criteria, reporting 465 patients (526 CBTs) with a mean age of 39.8 years. The treated CBTs were a mean size of 4.9 cm. Patients treated with surgery with the use of adjunct endovascular interventions had a mean blood loss of 368.4 mL (range, 25-to 2000 mL). There were 57 cranial nerve injuries, of which 28 (49.1%) were permanent. Cerebrovascular accident occurred in nine patients, of which one died. Hospital stay was a mean of 4.4 days (range, 2-17 days).**
Conclusions: **Preoperative selective endovascular embolization in patients with Shamblin II and Shamblin III CBTs may be beneficial when competently performed by interventional physicians proficient in neurovascular microcatheterization/embolization procedures. (J Vasc Surg 2015;61:1081-91.)**

The carotid body is a chemoreceptor located at the bifurcation of the common carotid artery (CCA) attached to the posteromedial surface of the adventitia by a thin strand (the Meyer ligament). Physiologically, it is highly responsive to hypoxia and less to hypercapnia and acidosis. Carotid body stimulation results in an increase in the respiratory rate, tidal volume, heart rate, and blood pressure secondary to vasoconstriction and the release of catecholamines.[1]

Carotid body tumors (CBTs) are rare indolent neoplasms that develop at the carotid bifurcation. With a reported incidence of one in 30,000 for Caucasians[2] and 1.6 in 10,000 annually,[3] they are an uncommon surgical entity, even at specialized tertiary referral vascular units. They most commonly occur in young women.[4,5] CBTs are usually unilateral and present sporadically but may also be encountered in clusters within families as part of multiple endocrine neoplasia type 2A and 2B syndromes.[6-8] It has become evident that CBTs develop in inhabitants of high altitudes with an increasing incidence in relation to altitude.[9,10]

The clinical presentation of CBTs entails a nonspecific sense of tightness in the shirt collar and less often neck stiffness or tenderness, or both.[11] Nonetheless, most patients with CBT seek consultation for an entirely symptom-free neck lump of increasing size. More specific symptoms are caused by the impingement of the adjacent cranial nerve (CN). Related symptoms may include dysphagia, hoarseness, and tinnitus. Rarely, CBTs may present as an unheralded stroke or transient ischemic attack. Their neurosecretory function may cause palpitations, headaches, diaphoresis, dizziness, and flushing.

CBTs have a natural history of significant and often unhindered size increase leading to the encasing of the adjacent neurovascular structures. Accordingly, as the size increases the morbidity of surgical resection rises; in addition, 5% of CBTs have a malignant course. A strong case can therefore be made for surgical resection at the earliest possible stage. Unfortunately, most patients with CBT seek medical attention when tumors have grown beyond Shamblin I stage.

Despite the advances in medical care, preoperative imaging, surgical technique, and the cumulative experience in management, the morbidity of CBTs remains alarmingly high, particularly with regard to CN dysfunction. Existing data reveal CN dysfunction occurs in 7% to 40%. In addition, in-hospital mortality exceeds 5%.[12] In a cumulative account of 4600 operations performed for CBTs in the United States, the mean length of stay was 9.2 (standard deviation, 13.5 days) in Northeast (n = 761), and mean hospital charges exceeded $26,000 (SD, 42,000) in the Midwest (n = 1021).[12] The need for adjunct supportive methods or interventions, or both, is compelling in light

From the Department of Surgery, Massachusetts General Hospital, Harvard Medical School, Boston[a]; the Society of Junior Doctors, Surgery Working Group, Athens[b]; and the Division of Vascular Surgery, Johns Hopkins Bayview Medical Center, Johns Hopkins Medical Institutions, Baltimore.[c]

Author conflict of interest: none.
Additional material for this article may be found online at www.jvascsurg.org.
Reprint requests: Konstantinos P. Economopoulos, MD, PhD, Department of Surgery, Massachusetts General Hospital, Harvard Medical School, 101 Merrimac St, Boston, MA 02114 (e-mail: keconomopoulos@mgh.harvard.edu).
The editors and reviewers of this article have no relevant financial relationships to disclose per the JVS policy that requires reviewers to decline review of any manuscript for which they may have a conflict of interest.
0741-5214
Copyright © 2015 by the Society for Vascular Surgery. Published by Elsevier Inc.
http://dx.doi.org/10.1016/j.jvs.2015.01.035

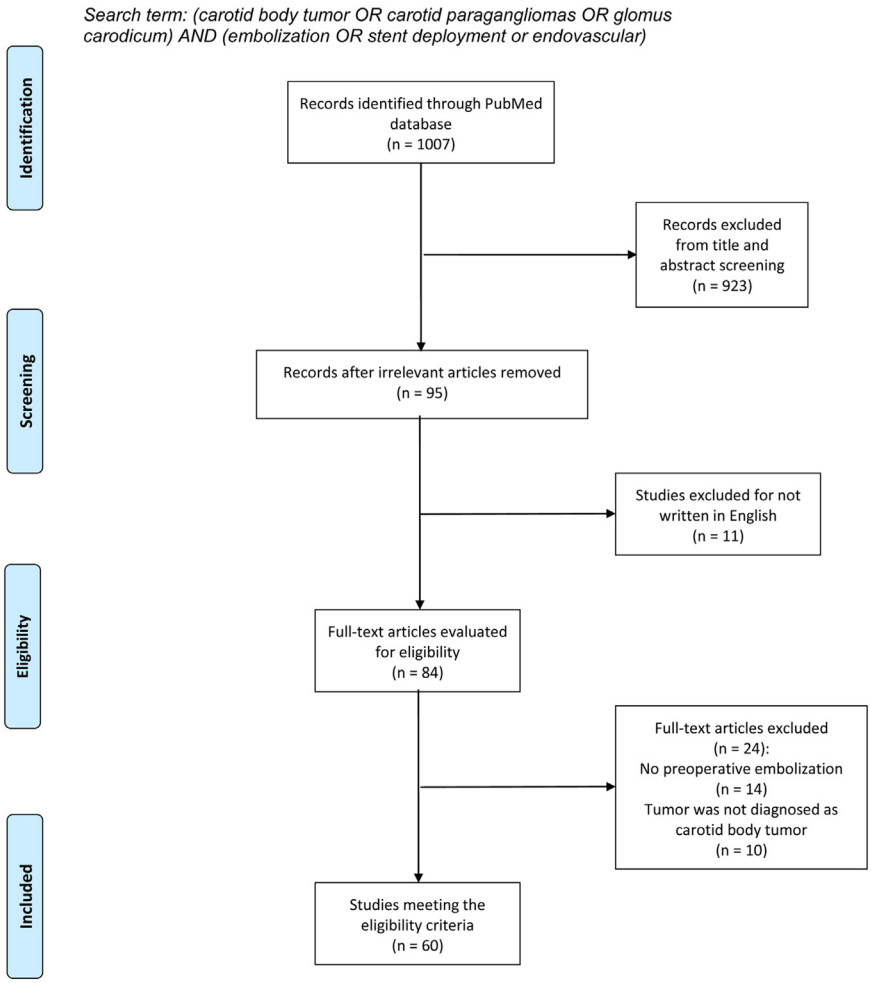

Fig. Preferred Reporting Items for Systematic Reviews and Meta-Analyses (PRISMA) flow diagram of the literature search.

of the clinical outcomes attached to the purely surgical treatment of Shamblin II to III CBTs. Possible preoperative interventions include embolization or placement of vascular stents, or both.

Embolization has been advocated as an effective method to reduce tumor vascularity and size. The rationale for preoperative embolization in large CBTs (Shamblin II or III) stems from the anatomic fact that a substantial proportion of the afferent arteries to the tumor arise from the external carotid artery (ECA), of which the most prominent is the ascending pharyngeal artery (ascending cervical).[13] Borges et al[14] were among the first to attempt preoperative embolization in two patients, enabling them to excise CBTs that would have otherwise posed a very substantial surgical risk due to their size and their tendency to encase adjacent neurovascular structures.

The aim of this study was to systematically review the current evidence from studies reporting patients with CBTs undergoing surgical treatment with the use of preoperative endovascular or embolization interventions, or both.

METHODS

Search strategy. The systematic review was conducted in accordance with the Preferred Reporting Items for Systematic Reviews and Meta-Analyses (PRISMA) guidelines and in line with the protocol agreed by all authors.[15] Eligible articles were identified by a thorough search of the PubMed bibliographic database extending from January 1967 to August 2013 (last search: August 18, 2013). Two investigators (K.P.E., and A.T.) working independently executed the search using the following keywords in all possible combinations: "carotid body tumor," "carotid paragangliomas," "glomus caroticum," "embolization," "stent deployment" and "endovascular." In addition, all of the references of relevant reviews and eligible articles that our search retrieved were checked.

Case reports or clinical series reporting patients with CBTs undergoing surgical treatment with the use of

Table I. Patient demographics and tumor-related characteristics of studies reporting on adjunct endovascular interventions for carotid body tumors (CBTs)

Study ID[a]	*Journal*	*Patients, No.*	*Tumors embolized, No.*	*Male/female, No.*	*Age, mean (range), years*	*Shamblin classification, No.*			*Tumor size, mean (range), cm*	*Malignant tumors, No.*
						I	*II*	*III*		
Schick, 1980	Surgery	1	1	1/0	21	–	–	–	–	0
Kumar, 1982	Am J Neuroradiol	2	3	1/1	49 (32-75)	–	–	–	–	0
Borges, 1983	J Neurosurg	2	3	1/1	31.5 (23-40)	–	–	–	3.3	0
Hennessy, 1984	Br J Radiol	1	1	0/1	13	–	–	–	5	0
DuBois, 1987	J Vasc Surg	1	2	1/0	28	–	–	–	5	0
Ward, 1988	Laryngoscope	6	6	3/3	49.2 (33-68)	–	–	–	–	0
Robison, 1989	Surg Gynecol Obstet	4	5	–	29-64	–	–	–	–	0
LaMuraglia, 1992	J Vasc Surg	–	11	–	23-78	–	–	–	–	0
Fruhwirth, 1996	Eur J Surg Oncol	3	3[b]	–	34-70	–	–	–	–	–
Litle, 1996	Ann Vasc Surg	11	11	4/7	46 (30-62)	2	6	3	5.0 (2.9-7.1)	–
Muhm, 1997	Arch Surg	8	8[b]	–	24-79	–	–	–	–	–
Westerband, 1998	J Vasc Surg	6	6	–	32-90	–	–	–	–	0
Iafrati, 1999	Cardiovasc Surg	1	1	1/0	72	0	0	1	8	0
Liapis, 2000	World J Surg	3	3	–	24-72	–	–	–	–	–
Kafie, 2001	Ann Vasc Surg	2	2	0/2	62.5 (50-75)	–	–	–	–	0
Horowitz, 2002	Ear Nose Throat J	1	1	0/1	37	0	1	0	–	0
Persky, 2002	Head Neck	27	28	–	–	–	–	–	6	0
Yilmaz, 2003	Ann Vasc Surg	5	5	2/3	–	–	–	–	(3-6)	0
Abud, 2004	Am J Neuroradiol	3	3	1/2	49 (33-67)	–	–	–	–	–
Harman, 2004	Acta Radiol	1	1	0/1	50	–	–	–	–	0
Tasar, 2004	J Craniofacial Surg	5	5	3/2	39.8 (21-49)	–	–	–	–	0
Puggioni, 2005	Perspect Vasc Surg Endovasc Ther	1	1	0/1	81	0	0	1	–	0
Antonitsis, 2006	Langenbecks Arch Surg	–	11	–	25-65	–	–	–	–	0
Kollert, 2006	Skull Base	10	10[b]	–	–	–	–	–	–	0
Singh, 2006	Inter Cardiovasc Thorac Surg	4	4[b]	–	18-42	–	–	–	–	0
Kasper, 2007	Vasc Endovasc Surg	–	13	–	28-83	–	–	–	4.2	0
Krishnamoorthy, 2007	Korean J Radiol	1	1	1/0	52	–	–	–	–	0
Karatas, 2008	Auris Nasus Larynx	1	2	1/0	49	–	–	–	4.5	0
Pecorari, 2008	Head Neck	1	1	0/1	37	0	1	0	–	0
Siedek, 2008	Eur Arch Otorhinolaryngol	2	2	–	–	0	2	0	–	0
Elhammady, 2009	J Neurosurg	1	1	1/0	70	–	–	–	–	0
Karaman, 2009	J Craniofac Surg	13	14	–	–	6	5	3	3.69 (2-8)	0
Martinelly, 2009	J Exp Clin Cancer Res	–	7	–	–	0	3	4	–	0
Siedek, 2009	Eur Arch Otorhinolaryngol	2	2	–	–	0	2	0	(4-4.5)	0
Vogel, 2009	Vasc Endovasc Surg	129	129[b]	39/90	51.2	–	–	–	–	–
Wanke, 2009	Am J Neuroradiol	4	6	1/3	44.3 (32-67)	–	–	–	3.5 (2-5)	–
Zeitler, 2009	Ann Otol Rhinol Laryngol	10	10	4/6	41 (22-72)	–	–	–	4.8 (2.9-8.3)	–
Hall, 2010	J Laryngol Otol	1	1	0/1	66	–	–	–	1.6	1
Li, 2010	Neurosurgery	33	36	15/18	40.2 (21-66)	0	11	25	(4-11)	1
Lim, 2010	Clin Exp Otorhinolaryngol	6	7	–	–	0	4	3	3.5 (2.2-5.5)	0
Ozyer, 2010	Cardiovasc Intervent Radiol	7	7	1/6	49.4 (32-75)	–	–	–	3 (2.5-4.5)	0
Wiegand, 2010	J Vasc Surg	1	1	0/1	20	0	0	1	7	0
Avgerinos, 2011	Vascular	4	4	–	–	0	2	2	–	–
Fennessy, 2011	Ir J Med Sci	1	1	1/0	18	–	–	–	2.5	0
Gemmete, 2011	J Neuro Intervent Surg	1	1	1/0	60	–	–	–	3.9	0
Gwon, 2011	World J Surg	14	14	–	–	–	–	–	–	–
Sahin, 2011	VASA	12	12	5/7	38.9 (21-66)	5	7	0	(2.5-5.1)	0
Shah, 2011	J Neuro Intervent Surg	7	7	4/3	47 (18-69)	–	–	–	2.7 (1.6-4.1)	0
Yang, 2011	J Chin Med Assoc	2	2	1/1	43 (24-62)	–	–	–	–	0
Alaraj, 2012	Neurosurg Res	1	1	0/1	23	–	–	–	4.8	0
Elhammady, 2012	World Neurosurg	9	9	–	–	–	–	–	–	–
Nazari, 2012	Acta Med Iran	3	3	–	–	–	–	–	4.36	0
Power, 2012	J Vasc Surg	29	33	8/21	47	0	21	12	4.7 (1.7-8)	0
San Roberto, 2012	J Vasc Surg	1	1	0/1	81	0	1	0	3.4	0
Zhang, 2012	Ann Vasc Surg	21	21	–	47 (28-61)	2	14	5	4.5 (2.8-6)	0
Abdel-Aziz, 2013	Head Neck Oncol	5	5	0/5	58.2 (32-78)	–	–	–	2.7 (2.3-3.2)	0
Cvjetko, 2013	J Craniofacial Surg	1	1	1/0	60	0	1	0	8	0
Fruhmann, 2013	Eur J Vasc Endovasc Surg	8	8	–	54.9 (31.8-78.8)	–	–	–	4.1 (2-5.5)	0
Sen, 2013	J Vasc Surg	15	16	–	–	0	2	14	5	0
Kalani, 2013	Neurosurgery	11	12	5/6	48.1 (36-72)	–	–	–	4.7 (1.7-9.3)	–
Total No., mean (range), or No. (%)		465	526	107 (35.3)/ 196 (64.7)	39.8 (13-81)	15 (8.7)	83 (48.3)	74 (43.0)	4.9 (1.6-11)	2

[a]For the references of eligible articles, please see the Supplementary Table (online only).
[b]Number of patients (number of tumors may be higher).

Table II. Exhaustive level of studies reporting on adjunct endovascular interventions for carotid body tumors (CBTs) including a comprehensive account of clinical perioperative outcomes

Trial ID[a]	*OR duration, mean (range), minutes*	*Blood loss, mean (range), mL*	*Duration between embolization and surgery, days*	*Ligation, No. (artery)*	*ECA division, No.*
Schick, 1980	–	–	–	–	–
Kumar, 1982	–	500	1	–	–
Borges, 1983	–	–	1-4	–	–
Hennessy, 1984	–	–	2	–	–
DuBois, 1987	–	–	2	–	–
Ward, 1988	–	397	1	–	–
Robison, 1989	–	332 (50-900)	1-2	–	–
LaMuraglia, 1992	270	373 (159-585)	1-2	–	4
Fruhwirth, 1996	–	–	–	–	–
Litle, 1996	306	1123	0-6	3 (ECA) + 2 (ICA)	–
Muhm, 1997	–	–	–	–	–
Westerband, 1998	–	–	–	–	–
Iafrati, 1999	–	150	1	–	1
Liapis, 2000	–	400	15	–	–
Kafie, 2001	–	200	1	–	–
Horowitz, 2002	–	–	1	–	–
Persky, 2002	–	517 (50-2000)	2	–	–
Yilmaz, 2003	–	200 (100-250)	Several days	–	–
Abud, 2004	–	–	2	–	–
Harman, 2004	–	100	1	–	–
Tasar, 2004	–	–	–	–	–
Puggioni, 2005	–	–	1	–	–
Antonitsis, 2006	–	–	2	–	–
Kollert, 2006	–	–	–	–	–
Singh, 2006	–	–	–	–	–
Kasper, 2007	–	365 (185-545)	1-2	–	–
Krishnamoorthy, 2007	–	–	–	–	–
Karatas, 2008	–	–	180	–	–
Pecorari, 2008	–	450	1	–	–
Siedek, 2008	–	–	1	–	–
Elhammady, 2009	–	50	2	–	–
Karaman, 2009	–	–	2	4 (ECA)	4
Martinelly, 2009	–	–	1–2	–	7
Siedek, 2009	120	235	1	–	–
Vogel, 2009	–	–	–	–	–
Wanke, 2009	207.6 (125-350)	183.3 (150-250)	5	–	–
Zeitler, 2009	–	305 (50-1000)	3	1 (ECA)	–
Hall, 2010	–	–	–	–	–
Li, 2010	170.3	354.8	1-6	8 (ECA)	–
Lim, 2010	360 (180-540)	400 (200-1200)	2	–	–
Ozyer, 2010	–	–	2	–	–
Wiegand, 2010	–	100#	0.5	–	–
Avgerinos, 2011	–	415 (230-850)	2	4 (ECA)	–
Fennessy, 2011	–	–	–	–	–
Gemmete, 2011	–	–	–	–	–
Gwon, 2011	–	–	2-3	1 (ICA)	–
Sahin, 2011	–	–	2	–	–
Shah, 2011	–	55 (15-80)	1	–	–
Yang, 2011	–	100	1	–	–
Alaraj, 2012	–	500	35	–	–
Elhammady, 2012	–	506	2.5	1 (carotid)	–
Nazari, 2012	–	–	–	–	–
Power, 2012	250	263	1	3 (ECA)	–
San Roberto, 2012	78	115.2	0	–	–
Zhang, 2012	180 (160-220)	280 (50-850)	1-2	–	–
Abdel-Aziz, 2013	148 (35-289)	327 (40-1400)	1	0	–
Cvjetko, 2013	–	230	2	–	–
Fruhmann, 2013	–	–	–	–	–
Sen, 2013	201.6	–	1	–	–
Kalani, 2013	–	191.6 (25-600)	1	–	–
Total No. or mean (range), or No. (%)	219.8 (78-540)	368.4 (25-2000)	2.9 (0.5-180)	27 (19.9)	16 (48.5)

CN, Cranial nerve; *CVA,* cerebrovascular accident; *ECA,* external carotid artery; *ICA,* internal carotid artery; *OR,* operation; *TIA,* transient ischemic attack.
[a]For the references of eligible articles please see the Supplementary Table (online only).

endovascular or embolization interventions, or both, were included. Articles were also identified by using the "related articles" function in PubMed. Discrepancies were discussed, and the list of the articles that best matched the inclusion criteria was finalized.

Data extraction. For each one of the eligible studies, the following data were extracted: absolute number of patient with CBTs that were managed surgically with the use of adjunct endovascular procedures, number of CBTs embolized, patient demographic data, Shamblin

Table II. Continued.

CN damage, No.														*Morbidity, No.*					
Total (permanent + temporary)							*Permanent*												
VII	*IX*	*X*	*XI*	*XII*	*Horner*	*ALL*	*VII*	*IX*	*X*	*XI*	*XII*	*Horner*	*ALL*	*TIA*	*CVA*	*Respiratory failure*	*Heart failure*	*Mortality, No.*	*Hospital stay, mean (range), days*
–	–	–	–	–	–	–	–	–	–	–	–	–	–	–	–	–	–	0	–
–	–	–	–	–	–	–	–	–	–	–	–	–	–	–	–	–	–	0	–
0	0	0	0	0	0	0	0	0	0	0	0	0	0	–	–	–	–	0	–
0	0	0	0	0	0	0	0	0	0	0	0	0	0	–	–	–	–	0	–
0	0	0	0	0	0	0	0	0	0	0	0	0	0	–	–	–	–	0	–
0	0	0	0	0	0	0	0	0	0	0	0	0	0	0	0	0	0	0	–
0	0	0	0	0	0	0	0	0	0	0	0	0	0	–	–	–	–	0	–
1	0	0	0	0	0	1	0	0	0	0	0	0	0	0	1	0	0	0	–
–	–	–		–	–	–	–	–	–	–	–	–	–	–	–	–	–	–	–
–	1	2	–	1	–	5	–	–	–	–	–	–	–	0	0	–	0	0	–
–	–	–	–	–	–	–	–	–	–	–	–	–	–	0	0	–	–	0	–
–	–	–	–	–	–	–	–	–	–	–	–	–	–	0	1	–	–	0	–
–	–	–	–	–	–	–	–	–	–	–	–	–	–	0	0	1	0	0	–
–	–	–	–	–	–	1	–	–	–	–	–	–	–	0	0	–	–	0	(4-5)
–	–	–	–	–	–	–	–	–	–	–	–	–	–	0	0	0	0	0	–
–	–	–	–	–	–	–	–	–	–	–	–	–	–	–	–	–	–	0	–
0	9	5	1	1	6	22	0	0	2	0	1	6	9	–	–	–	–	0	–
0	0	0	0	0	0	0	0	0	0	0	0	0	0	0	0	0	0	0	–
0	0	0	0	0	0	0	0	0	0	0	0	0	0	0	0	0	0	0	–
–	–	–	–	–	–	–	–	–	–	–	–	–	–	–	–	–	–	0	–
0	0	0	0	0	0	0	0	0	0	0	0	0	0	0	0	0	0	0	–
0	1	1	0	1	0	3	–	–	–	–	–	–	–	–	–	–	–	0	–
–	–	–	–	–	–	–	–	–	–	–	–	–	–	0	0	0	0	0	–
0	0	0	0	0	0	0	0	0	0	0	0	0	0	0	0	–	–	–	–
–	–	–	–	–	–	–	–	–	–	–	–	–	–	–	–	–	–	0	–
–	–	–	–	–	–	–	–	–	–	–	–	–	–	–	–	–	–	0	2.6
0	0	0	0	0	0	0	0	0	0	0	0	0	0	0	1	0	0	0	–
0	0	1	0	0	0	1	0	0	1	0	0	0	1	0	0	0	0	0	–
0	0	0	0	0	0	0	0	0	0	0	0	0	0	0	0	0	0	0	4
0	0	1	0	0	0	1	0	0	0	0	0	0	0	0	0	0	0	0	–
0	0	0	0	0	0	0	0	0	0	0	0	0	0	0	0	0	0	0	2
0	0	0	0	0	0	0	0	0	0	0	0	0	0	0	0	0	0	0	–
–	–	–	–	–	–	–	–	–	–	–	–	–	–	0	0	–	–	0	–
0	0	1	0	0	0	1	0	0	1	0	0	0	1	0	0	0	0	0	–
–	–	–	–	–	–	–	–	–	–	–	–	–	–	0	0	0	0	0	3.48
0	0	0	0	0	0	0	0	0	0	0	0	0	0	0	0	0	0	0	–
0	0	0	0	2	0	2	0	0	0	0	0	0	0	0	0	0	0	0	–
–	–	–	–	–	–	–	–	–	–	–	–	–	–	–	–	–	–	0	–
0	0	1	0	0	0	1	0	0	1	0	0	0	1	1	0	0	0	0	8
0	0	–	0	–	0	0	0	0	–	0	–	0	0	–	0	0	0	–	8 (4-12)
0	0	0	0	0	0	0	0	0	0	0	0	0	0	0	0	0	0	0	–
0	1	0	0	1	1	3	0	0	0	0	0	1	1	0	0	0	0	0	–
1	1	1	1	1	0	5	1	1	1	1	1	0	5	0	0	0	0	–	4.8
0	0	0	0	0	0	0	0	0	0	0	0	0	0	–	–	–	–	0	–
–	–	–	–	–	–	–	–	–	–	–	–	–	–	1	–	–	–	0	–
1	1	1	0	1	0	4	1	1	1	0	1	0	4	–	4	–	–	0	–
0	0	0	0	0	0	0	0	0	0	0	0	0	0	0	0	0	0	0	4.6 (4-7)
0	0	0	0	0	0	0	0	0	0	0	0	0	0	0	0	0	0	0	–
–	–	–	–	–	–	–	–	–	–	–	–	–	–	–	–	–	–	0	–
0	0	0	0	0	0	0	0	0	0	0	0	0	0	0	0	0	0	0	–
0	0	0	0	0	0	0	0	0	0	0	0	0	0	0	0	0	0	0	–
0	0	0	0	1	0	1	0	0	0	0	1	0	1	0	1	0	0	1	–
–	–	–	–	–	–	–	–	–	–	–	–	–	–	0	0	1	0	0	4.1 (2-17)
0	0	0	0	0	0	0	0	0	0	0	0	0	0	0	0	0	0	0	4
0	0	0	0	3	0	3	0	0	0	0	3	0	0	0	0	0	0	0	5 (4-8)
0	0	0	0	1	1	2	0	0	0	0	0	1	0	0	0	0	0	0	–
0	0	0	0	0	0	0	0	0	0	0	0	0	0	0	0	0	0	0	–
–	–	–	–	–	–	–	–	–	–	–	–	–	–	1	–	–	–	0	–
–	–	–	–	–	–	–	–	–	–	–	–	–	–	2	–	–	–	0	–
0	0	0	0	1	0	1	0	0	0	0	1	0	0	0	0	0	0	0	–
3 (5.3)	14 (24.6)	14 (24.6)	2 (3.5)	14 (24.6)	8 (14.0)	57 (100)	2 (7.1)	2 (7.1)	7 (25.0)	1 (3.6)	8 (28.6)	8 (28.6)	28 (100)	5 (1.1)	8 (1.7)	2 (0.4)	0 (0)	1 (0.2)	4.4 (2-17)

classification and tumor size, mean operative time, mean blood loss, number and type of ligated or divided arteries, duration between embolization and surgery, comprehensive clinical outcome reporting with emphasis on CN damage (VII, IX, X, XI, XII, and Horner syndrome), cerebrovascular morbidity, hospital length of stay, mortality, and detailed data on the applicable adjunct endovascular procedures (eg, embolization material used). Excluded

were studies published earlier than 1967 or studies that did not report specific data on demographics, methods, and clinical outcomes.

Statistical analysis. Outcome measures of eligible studies were tabulated and analyzed cumulatively. A purely descriptive approach was adopted, that is, data were expressed as nonweighted means whenever possible.

RESULTS

Article selection, patient demographics, and tumor-related characteristics. The literature search generated 1007 articles published in English, which were reviewed by two authors (K.P.E. and A.T.) working independently. Sixty studies met the criteria for this systematic review, none of which were randomized (Fig; Supplementary Table). There were 526 CBTs excised in 465 patients after the use of embolization. Patient demographics and tumor-related characteristics are summarized in Table I. Eligible patients were a mean age of 39.8 years (range, 13-81 years), and 65% were female. In the studies reporting Shamblin stages, 43% (74 of 172) were stage III, 48% (83 of 172) were stage II, and 9% (15 of 172) were stage I. Tumors treated with preoperative embolization and surgical excision were a mean size of 4.9 cm (range 1.6-11 cm). Only two patients (0.6%) were treated for malignant disease.

Perioperative outcomes, morbidity, and mortality. Perioperative data are summarized in Table II. The mean operative time was 219.8 minutes (range, 78-540 minutes). The mean blood loss of patients treated with surgery and the use of adjunct endovascular interventions was 368.4 mL (range, 25- 2000 mL). The time between the endovascular intervention and the surgical excision was 12 hours to 6 months, but the CBT in 75% of the studies was excised within the first 2 days after the endovascular procedure.

Eight studies reported ligation of the ECA or internal carotid artery (ICA). Especially ligation of the ECA was performed in 23 patients, whereas the ICA was ligated in three patients only. ECA division was performed in 16 cases, of which four ECA were ligated and divided in advance due to the large size of the tumor (Shamblin III). There were 51 CN injuries of which 23 were permanent. Injuries occurred to the glossopharyngeal nerve in 14, vagus nerve in 14, hypoglossal nerve in 14, the sympathetic nerve, causing Horner syndrome, in 8, and accessory nerve in 2. However, permanent CN injury was higher for the sympathetic nerve (n = 8) and the hypoglossal nerve (n = 8). One patient died of a stroke due to the endovascular intervention before surgical excision. A cerebrovascular accident occurred in seven more patients during surgical excision, and one died. Hospital stay was a mean of 4.4 days (range, 2-17 days).

Embolization materials. The embolization materials and size of particles being used during adjunct endovascular interventions are reported in Table III. Polyvinyl alcohol (PVA) particles were the most commonly used embolization material, and most of the studies used particles that were 150 to 500 μm in diameter.

DISCUSSION

In 1992, LaMuraglia et al[16] successfully performed preoperative embolization with PVA particles (range, 150-300 μm) and Gelfoam (Pfizer, New York, NY) in 10 of 11 patients with large CBTs, achieving a significant elimination of tumor vascularity. The LaMuraglia report[16] was followed by the case series by Litle et al[17] in the 1990s, and since 2002, 12 additional studies[18-29] constitute the main body of clinical data on the clinical feasibility of embolization in the management of CBTs (Tables I and II). Their manuscripts include almost 70% (361 of 526) of the reported tumors that underwent preoperative embolization with the aim of causing tumor vascularity to decrease and tissue volume to shrink.

With regard to the demographic characteristics, patients treated with preoperative embolization and surgical excision were 35% male and an average age of 40 years. From the case series included in this study, seven reported an additional group of patients with CBTs treated only with surgery (Table IV). In these studies, patients treated only with surgical excision were 47% male and on average in their early 50s (vs 40% male and late 40s in the embolization group).

Unfortunately, the Shamblin classification has been adopted in only 19 of 60 (32%) of the eligible studies,[11,17,21,23,25-28,30-39] and therefore, the benefit of preoperative embolization in CBTs of the highest size grade has yet to be demonstrated. The size of tumors treated with preoperative embolization and surgical excision was 1.6 to 11 cm, almost the same (range, 2-12 cm) in the patients treated with surgery only (Table IV). Malignant CBTs are extremely rare and were almost always treated with surgery. Preoperative embolization has been performed in only two patients (0.6%) to date.

Eleven studies[16,17,23,26-28,34,35,38,40,41] referred to the operative times, which averaged 3.7 hours among patients undergoing CBT surgery after embolization. Among those who had not had embolization, operative times were longer in the LaMuraglia et al series (4.5 hours)[16] and in the report by Litle et al[17] (3.9 hours), suggesting that embolization of CBTs makes the excision of the tumor easier for the surgeon. The time between preoperative embolization and open surgery was 1 to 2 days in most large-sized series. In three reports,[42-44] the preoperative embolization was performed 15 days, 35 days, and 6 months before the operation, respectively, with beneficial effects.

Blood loss appears to be well contained among those undergoing preoperative embolization, with a mean of 368.4 mL (ranging, 25-2000 mL) in 30 reports that accounted for blood loss. LaMuraglia et al[16] performed linear regression analysis between the operative blood loss vs the tumor surface area and identified a statistically significant difference between the slope of those who had and had not undergone embolization, allowing them to conclude that preoperative embolization was able to decrease operative

Table III. Adjunct endovascular interventions for carotid body tumors[a]

Trial ID[b]	*Embolization materials*	*Size of particles*
Schick, 1980	PVA foam sponge particles	–
Kumar, 1982	Microfibrillar collagen + contrast material+ temporary balloon occlusion of the ECA	1.5-4 mL embolic material
Borges, 1983	PVA particles + iothalamate meglumine 60%	150-μm PVA particles
Hennessy, 1984	Sterile absorbable gelatin sponge	–
DuBois, 1987	PVA foam sponge particles	0.25-0.5 mm
Ward, 1988	PVA particles	100-250 μm
Robison, 1989	PVA particles	–
LaMuraglia, 1992	PVA beads + Gelfoam (Pfizer, New York, NY)	150-300 μm
Fruhwirth, 1996	Gelfoam	–
Litle, 1996	PVA particles	200-500 μm
Muhm, 1997	PVA particles	250 μm
Westerband, 1998	–	–
Iafrati, 1999	PVA particles	250-500 μm
Liapis, 2000	PVA Gelfoam	150-300 μm
Kafie, 2001	Gel solution (6% Onyx Micro Therapeutics, Irvine, Calif)	–
Horowitz, 2002	Temporary balloon occlusion + ethanol injection	1.8 mL 100% alcohol for 15 min
Persky, 2002	PVA particles or Gelfoam or cyanoacrylate	–
Yilmaz, 2003	Calibrated microsphere particles	–
Abud, 2004	Acrylic glue (Glubran 2; GEM Srl, Viareggio, Italy)	3-13 mL
Harman, 2004	PVA particles + 3 NBCA (Hystoacryl; B. Braun Melsnagen, Germany) and 1 Lipiodol (Guerbet, Aulnay-Sous-Bois, France)	6 ml of Lipiodol/NBCA + 350-510-μm particles
Tasar, 2004	Helical platinum nonferromagnetic microcoils (Target Therapeutics) + PVA (Contour Emboli, Interventional Therapeutic Co, San Francisco, Calif; Target Vascular, Boston Scientific, Fremont, Calif), or acrylic polymer microspheres (Embosphere R microspheres; Biosphere, Rockland, NY)	300-1000 μm
Puggioni, 2005	PVA particles	–
Antonitsis, 2006	Microcoils (William Cook Europe, Denmark) + Gelfoam + PVA particles	–
Kollert, 2006	–	–
Singh, 2006	–	–
Kasper, 2007	PVA particles	100-750 μm
Krishnamoorthy, 2007	Polymerized glue (NBCA)	Percutaneous injection of 50% glue
Karatas, 2008	PVA particles (Boston Scientific, Watertown, Mass) + Ultravist (Schering, Germany)	355-500 mL PVA + 100 mL Ultravist 370 mg/mL
Pecorari, 2008	PVA particles	150 μm
Siedek, 2008	Coils or cyanoacrylate	–
Elhammady, 2009	EVOH copolymer (Onyx Micro Therapeutics)	5 mL Onyx-34
Karaman, 2009	Straight and curled Microcoils (William Cook Europe, Denmark) + Gelfoam + PVA	
Martinelly, 2009	–	–
Siedek, 2009	Coils (cyanoacrylate in 1 patient)	–
Vogel, 2009	–	–
Wanke, 2009	EVOH copolymer (Onyx Micro Therapeutics)	3.0-9.1 mL Onyx-18
Zeitler, 2009	PVA particles	–
Hall, 2010	–	–
Li, 2010	PVA particles + Gelfoam (less with microcoil)	300-500-μm diameter
Lim, 2010	PVA	–
Ozyer,2010	PVA particles (Boston Scientific) + NBCA injections	355-500-μm or 500-710-μm PVA particles
Wiegand, 2010	EVOH copolymer (Onyx Micro Therapeutics, Irvine, Calif)	20 mL Onyx
Avgerinos, 2011	PVA	–
Fennessy, 2011	–	–
Gemmete, 2011	Coils (Microvention, Aliso Viejo, Calif) + Embospheres (BioSphere Medical, Rockland, Mass)	2-mm × 2-cm HydroCoil 10 coils, 2-mm × 4-cm HydroCoil 10 coils, 3-mm × 5-cm HydroCoil 14 coils, 3-mm × 7-cm HydroCoil 14 coils, 4-mm × 10-cm HydroCoil 14 coils, + 100-300-μm particles of Embosphere
Gwon, 2011	PVA particles + Gelfoam	–
Sahin, 2011	PVA (contour PVA embolization particles) or Glubran 2 injection (glue)	350-500-μm particles
Shah, 2011	EVOH copolymer (Onyx Micro Therapeutics, Irvine, Calif)	8% EVOH (Onyx 34) + DMSO (average 8.7 mL of EVOH)
Yang, 2011	NBCA glue	15 mL low concentration of NBCA
Alaraj, 2012	EVOH copolymer (Onyx Micro Therapeutics, Irvine, Calif)	Onyx-34, 2 stages of embolization
Elhammady, 2012	EVOH copolymer (Onyx Micro Therapeutics, Irvine, Calif)	8.4 mL Onyx-18 (lower viscosity)/Onyx-34 (higher), or both
Nazari, 2012	–	–
Power, 2012	PVA particles	Small (150-250-μm) particles + large (up to 1000 μm)
San Roberto, 2012	Poloxamer 407 (LeGoo; Pluromed, Woburn, Mass)	1 mL poloxamer
Zhang, 2012	PVA particles (Contour; Interventional Therapeutics Corp, San Francisco, Calif) + platinum coils (Target Therapeutics) + electrolytically detachable coils (Guglielmi detachable coils, Target Therapeutics)	150-500-μm PVA particles
Abdel-Aziz, 2013	EVOH copolymer (Onyx Micro Therapeutics, Irvine, Calif)	4.4 (1-9) mL
Cvjetko, 2013	Coils	5 pieces, 3-5 mm
Fruhmann, 2013	–	–

(*Continued on next page*)

Table III. Continued.

Trial ID[b]	*Embolization materials*	*Size of particles*
Sen, 2013	PVA particles + gelatin foam	–
Kalani, 2013	EVOH copolymer (Onyx Micro Therapeutics, Irvine, Calif) + coils + NBCA	4% alcohol (Onyx 18)

DMSO, Dimethyl sulfoxide; *ECA,* external carotid artery; *EVOH,* ethylene vinyl alcohol; *NBCA, n*-butyl-2-cyanoacrylate; *PVA,* polyvinyl alcohol.
[a]Updated exhaustive list of pertinent publications with reported number of patients and tumors and a detailed account of the materials used and size of particles.
[b]For the references of eligible articles, please see the Supplementary Table (online only).

Table IV. Patient demographics, tumor-related characteristics, and clinical perioperative and postoperative outcomes of comparative studies reporting outcomes after treatment of carotid body tumors (CBTs) with and without embolization procedures

Trial ID[a]	*Groups*	*Patients, No.*	*Tumors, No.*	*Male/female, No. (%)*	*Shamblin classification, No. (%)*			*Age,*[b] *years*	*Tumor size, mean (range), cm*	*Blood loss,*[b] *mL*	*OR duration,*[b] *min*	*Hospital stay,*[b] *days*	*Complications, No. (%)*	
					I	*II*	*III*						*Stroke*	*CN deficit*
Litle, 1996	EMB	11	11	–	2	6	3	–	–	1123 ± 1450	306 ± 150	0.8 ± 0.4	0	5
	NEMB	11	11	–	5	2	4	–	–	764 ± 588	234 ± 96	1.5 ± 0.8	1	5
Vogel, 2009	EMB	129	129	–	–	–	–	51.2 ± 17.1	–	–	–	–	–	–
	NEMB	1686	1686	–	–	–	–	54.3 ± 16.6	–	–	–	–	–	–
Zeitler, 2009	EMB	10	10	6/4	–	–	–	41 (22-72)	4.8 (2.9-8.3)	305 (50-1000)	–	–	–	3
	NEMB	15	15	9/6	–	–	–	43.7 (22-72)	4.4 (2.8-7.9)	265.6 (40-900)	–	–	–	2
Li, 2010	EMB	33	36	15/18	0	11	25	40.2 (21-66)	(4-11)	354.8 6 ± 334.4	170.3 ± 75.4	8.0 ± 2.1	1	1
	NEMB	29	30	12/17	0	9	21	44.3 (23-71)	(5-12)	656.4 ± 497.4	224.6 ± 114.0	9.5 ± 3.5	3	4
Lim, 2010	EMB	6	7	–	0	4	3	–	3.5 (2.2-5.5)	360 (180-540)	360 (180-540)	8 (4-12)	–	–
	NEMB	6	6	–	1	0	5	–	3.9 (2-5.5)	550 (200-1400)	360 (220-480)	8 (6-10)	–	–
Power, 2012	EMB	29	33	8/21	0	21	12	47	4.7 (1.7-8)	–	–	5.1 (3-18)	0	5
	NEMB	69	71	32/37	0	50	21	48	4.1 (2.5-7)	–	–	4.4 (2-31)	1	9
Zhang, 2012	EMB	21	21	–	2	14	5	–	4.5 (2.8-6.0)	280 (50-850)	180 (160-220)	5 (4-8)	–	–
	NEMB	8	8	–	1	5	2	–	3.9 (2.5-5.5)	450 (100-1000)	220 (170-260)	8 (6-11)	–	–
Total	EMB	239	246	29 (40.3)/43 (59.7)	4 (3.7)	56 (52.3)	47 (43.9)	48.3 (21-72)	4.5 (1.7-11)	430.21	210.5	5.8	1 (1.25)	14 (15.5)
	NEMB	1824	1827	53 (46.9)/60 (53.1)	7 (5.5)	66 (52.4)	53 (42.1)	53.8 (22-72)	4.1 (2-12)	556.6	240.25	5.8	10 (8.9)	20 (15.7)

CN, Cranial nerve; *EMB,* preoperative embolization used; *NEMB,* preoperative embolization not used; *OR,* operation.
[a]For the references of eligible articles, please see the Supplementary Table (online only).
[b]Data are shown as mean (range) or as mean ± standard deviation.

bleeding. Kasper et al,[20] failed to identify a significant difference in blood loss when embolization was used, yet those undergoing surgery alone had a significantly lower mean Shamblin classification (1.45 vs 2.5; $P < .001$), rendering comparison on blood loss biased in favor of the latter.

With respect to total and permanent CN damage, the information provided did not discriminate between the subgroups of those undergoing preoperative embolization and open surgery and those undergoing open surgery alone, thus making it impossible to determine the efficacy of embolization, if any, on the preservation of CN function. There are reports of 57 CN injuries among more than 526 CBTs; regrettably, almost half of the studies provided no detailed account of how many of these were permanent (28 permanent of 57 total). Furthermore, no details were provided about the type of CN injury sustained, except in six series, indicating a higher damage propensity for the vagus, hypoglossal, and glossopharyngeal nerves.[16-18,32,34,43] Embolization, when compared with an equally sized control group, provided a marked decrease in CN damage (total: 5 vs 10; permanent: 0 vs 4) and a shorter postoperative hospital stay, whereas embolization failed to improve the blood loss or transfusion requirement, the operative time, and perioperative morbidity.[17]

There are at least 7 reported episodes of CVA (1.7%) and at least 5 episodes of transient ischemic attack (1.1%) associated with preoperative embolization, 4 strokes reported by Gwon et al,[24] 1 reported by Westerband et al,[45] and Krishnamoorthy et al,[46] respectively, and 1 transient episode of aphasia in a tortuous carotid artery referred to by LaMuraglia et al.[16] One patient died of stroke.[1] Vogel et al[22] reported 129 patients with CBTs, the largest series to date managed with combined endovascular and surgical treatment (Table IV). Patients treated with surgery with carotid artery reconstruction were more likely to experience stroke (odds ratio, 5.9) and postoperative hemorrhage (odds ratio, 26.6) compared with those treated with preoperative embolization and surgery. To date, one patient death has been reported after undergoing embolization, followed by surgery.[1] Robison et al[47] reported one death from unrelated causes 3 years after the procedure. In Vogel et al,[22] no perioperative deaths

occurred in the embolization group, whereas 15 patients (0.8%) died in the excision group. However, after adjusting for age, sex, and comorbidities, the authors did not find significant differences in mortality.

Embolization technique and materials. The risk potential of preoperative embolization causing thrombosis of the carotid arterial system or cerebral embolization, or both, or another major morbidity is significant, even in the hands of experienced interventional radiologists. However, improvements in instrumentation, in particular, the advent of microcatheters and flexible guidewires, as well as the production of safer and more effective embolic materials, alongside the experience gained in specialized units, have increased the feasibility and clinical efficacy of this intervention, thus making a case for its application in selected patients with large CBTs.

Agents used to embolize vasculogenic tumors are generally stratified into three categories: mechanical devices, particles, and liquids. Which one should be best used mainly depends on hemodynamic and angioarchitectural factors. Gelfoam, microcoils, cyanoacrylate, ethylene vinyl alcohol, and PVA have so far been used with variable embolization efficacy, as presented in Table III.

LaMuraglia et al[16] performed embolization by the introduction of a 150 to 300 μm PVA foam sponge particles into CBTs microvascular and infused Gelfoam into the artery main branches to obliterate arterial inflow. Persky et al[18] also alluded to the efficacy of these materials in addition to cyanoacrylate, a polymerizing glue with more permanent results. Litle et al[17] used 200 to 500 μm PVA particles, Kasper et al[20] used 100 to 750 μm PVA particles, and Antonitsis et al[19] was in favor of the use of microcoils. The use of these materials on embolization continues until a significance reduction (>60%) is noted in the tumor blush.[20]

The main objective is to direct the embolic material into the tumor selectively, eliminating only its vascularity, without occlusion of the feeding artery initially.[18] Avoiding proximal vessel occlusion with embolization may prevent the recruitment of ICA arterial supply to the tumor while providing future endovascular access in tumor recurrence.[18] A meticulous approach is obligatory, particularly during catheter manipulations and embolic material injections if particle reflex into the ophthalmic and cerebral circulation are to be avoided.[16]

Endovascular access to the CCA may be gained from the femoral or the brachial arteries, most common through the former, using a Simmons sidewinder II or III (Angio-Dynamics, Queensbury, NY), the Headhunter catheter (Cordis, Miami, Fla), or other catheters. When the common femoral artery (CFA) is used, a 7F shuttle access sheath can be forwarded over a stiff angled guidewire (Terumo Medical Corp), or a Supracore guidewire (Guiding Corp, Indianapolis, Ind). The availability of microcatheters (Target Therapeutics, San Jose, Calif; Terumo Medical Corp) enables selective access to small feeding vessels, particularly with the aid of greater stability provided by 5F multipurpose catheters anchored through the ECA take off.[48]

Alternative access to the feeding vessels of the CBTs, which may be combined with an endovascular approach, may be gained percutaneously.[49] The least vasculogenic tumor portion may be directly punctured with a 20-gauge angiographic needle under continuous ultrasound guidance. A pilot starting contrast dose may be injected into the tumor interstitium, thus allowing superimposition and immediate comparison between the two angiographic CBT appearances, confirming the safety of the needle's placement. In a study by Puggioni et al,[32] the selective catheterization of the ascending pharyngeal artery using PVA particles resulted in a 60% to 70% attenuation of the vascularity and size of a large 15- × 5- × 4-cm CBT (Shamblin stage III), located 3 to 3.5 cm from the skull base, in a 81-year-old woman presenting with recent multiple episodes of syncope.[32]

Limitations. Selection bias is often present in all the published case series, including the eligible series of this analysis. However, selection bias is true for all treatment options, and more challenging cases will be successfully managed with increasing experience. In addition, the conclusions of this review are based solely on the available data, and often, some of the outcomes of interest are not reported. In summary, the current level of evidence on the use of endovascular interventions before CBT excision does not allow a fully objective evaluation of these preliminary results.

CONCLUSIONS

This study is a systematic review of adjunct endovascular interventions in the surgical management of CBTs. The use of preoperative selective endovascular embolization in patients with Shamblin II and III CBTs may be beneficial when competently performed by interventional physicians proficient in the neurovascular microcatheterization/embolization procedures.

AUTHOR CONTRIBUTIONS

Conception and design: KE
Analysis and interpretation: KE, AT, TR
Data collection: KE, AT
Writing the article: KE
Critical revision of the article: KE, AT, TR
Final approval of the article: KE, AT, TR
Statistical analysis: KE
Obtained funding: Not applicable
Overall responsibility: KE

REFERENCES

1. Nazari I, Aarabi Moghaddam F, Zamani MM, Salimi J. Clinical characteristics and remedies in 45 Iranians with carotid body tumors. Acta Med Iran 2012;50:339-43.
2. Bikhazi PH, Roeder E, Attaie A, Lalwani AK. Familial paragangliomas: the emerging impact of molecular genetics on evaluation and management. Am J Otol 1999;20:639-43.
3. Oosterwijk JC, Jansen JC, van Schothorst EM, Oosterhof AW, Devilee P, Bakker E, et al. First experiences with genetic counselling

based on predictive DNA diagnosis in hereditary glomus tumours (paragangliomas). J Med Genet 1996;33:379-83.
4. Gaylis H, Davidge-Pitts K, Pantanowitz D. Carotid body tumours. A review of 52 cases. S Afr Med J 1987;72:493-6.
5. Sajid MS, Hamilton G, Baker DM. A multicenter review of carotid body tumour management. Eur J Vasc Endovasc Surg 2007;34:127-30.
6. Heutink P, van der Mey AG, Sandkuijl LA, van Gils AP, Bardoel A, Breedveld GJ, et al. A gene subject to genomic imprinting and responsible for hereditary paragangliomas maps to chromosome 11q23-qter. Hum Mol Genet 1992;1:7-10.
7. Devilee P, van Schothorst EM, Bardoel AF, Bonsing B, Kuipers-Dijkshoorn N, James MR, et al. Allelotype of head and neck paragangliomas: allelic imbalance is confined to the long arm of chromosome 11, the site of the predisposing locus PGL. Genes Chromosomes Cancer 1994;11:71-8.
8. Mariman EC, van Beersum SE, Cremers CW, Struycken PM, Ropers HH. Fine mapping of a putatively imprinted gene for familial non-chromaffin paragangliomas to chromosome 11q13.1: evidence for genetic heterogeneity. Hum Genet 1995;95:56-62.
9. Pacheco-Ojeda L, Durango E, Rodriquez C, Vivar N. Carotid body tumors at high altitudes: Quito, Ecuador, 1987. World J Surg 1988;12:856-60.
10. Rodriguez-Cuevas S, Lopez-Garza J, Labastida-Almendaro S. Carotid body tumors in inhabitants of altitudes higher than 2000 meters above sea level. Head Neck 1998;20:374-8.
11. Martinelli O, Irace L, Massa R, Savelli S, Giannoni F, Gattuso R, et al. Carotid body tumors: radioguided surgical approach. J Exp Clin Cancer Res 2009;28:148.
12. Maxwell JG, Jones SW, Wilson E, Kotwall CA, Hall T, Hamann S, et al. Carotid body tumor excisions: adverse outcomes of adding carotid endarterectomy. J Am Coll Surg 2004;198:36-41.
13. Schick PM, Hieshima GB, White RA, Fiaschetti FL, Mehringer CM, Grinnell VS, et al. Arterial catheter embolization followed by surgery for large chemodectoma. Surgery 1980;87:459-64.
14. Borges LF, Heros RC, DeBrun G. Carotid body tumors managed with preoperative embolization. Report of two cases. J Neurosurg 1983;59:867-70.
15. Liberati A, Altman DG, Tetzlaff J, Mulrow C, Gotzsche PC, Ioannidis JP, et al. The PRISMA statement for reporting systematic reviews and meta-analyses of studies that evaluate health care interventions: explanation and elaboration. J Clin Epidemiol 2009;62:e1-34.
16. LaMuraglia GM, Fabian RL, Brewster DC, Pile-Spellman J, Darling RC, Cambria RP, et al. The current surgical management of carotid body paragangliomas. J Vasc Surg 1992;15:1038-44; discussion: 1044-45.
17. Litle VR, Reilly LM, Ramos TK. Preoperative embolization of carotid body tumors: when is it appropriate? Ann Vasc Surg 1996;10:464-8.
18. Persky MS, Setton A, Niimi Y, Hartman J, Frank D, Berenstein A. Combined endovascular and surgical treatment of head and neck paragangliomas—a team approach. Head Neck 2002;24:423-31.
19. Antonitsis P, Saratzis N, Velissaris I, Lazaridis I, Melas N, Ginis G, et al. Management of cervical paragangliomas: review of a 15-year experience. Langenbecks Arch Surg 2006;391:396-402.
20. Kasper GC, Welling RE, Wladis AR, CaJacob DE, Grisham AD, Tomsick TA, et al. A multidisciplinary approach to carotid paragangliomas. Vasc Endovascular Surg 2006;40:467-74.
21. Karaman E, Isildak H, Yilmaz M, Edizer DT, Ibrahimov M, Cansiz H, et al. Management of paragangliomas in otolaryngology practice: review of a 7-year experience. J Craniofac Surg 2009;20:1294-7.
22. Vogel TR, Mousa AY, Dombrovskiy VY, Haser PB, Graham AM. Carotid body tumor surgery: management and outcomes in the nation. Vasc Endovasc Surg 2009;43:457-61.
23. Li J, Wang S, Zee C, Yang J, Chen W, Zhuang W, et al. Preoperative angiography and transarterial embolization in the management of carotid body tumor: a single-center, 10-year experience. Neurosurgery 2010;67:941-8; discussion: 948.
24. Gwon JG, Kwon TW, Kim H, Cho YP. Risk factors for stroke during surgery for carotid body tumors. World J Surg 2011;35:2154-8.
25. Sahin MA, Jahollari A, Guler A, Doganci S, Bingol H, Karaman B, et al. Results of combined preoperative direct percutaneous embolization and surgical excision in treatment of carotid body tumors. Vasa 2011;40:461-6.
26. Power AH, Bower TC, Kasperbauer J, Link MJ, Oderich G, Cloft H, et al. Impact of preoperative embolization on outcomes of carotid body tumor resections. J Vasc Surg 2012;56:979-89.
27. Zhang TH, Jiang WL, Li YL, Li B, Yamakawa T. Perioperative approach in the surgical management of carotid body tumors. Ann Vasc Surg 2012;26:775-82.
28. Sen I, Stephen E, Malepathi K, Agarwal S, Shyamkumar NK, Mammen S. Neurological complications in carotid body tumors: a 6-year single-center experience. J Vasc Surg 2013;57:64S-8S.
29. Kalani MY, Ducruet AF, Crowley RW, Spetzler RF, McDougall CG, Albuquerque FC. Transfemoral transarterial onyx embolization of carotid body paragangliomas: technical considerations, results, and strategies for complication avoidance. Neurosurgery 2013;72:9-15; discussion: 15.
30. Iafrati MD, O'Donnell TF. Adjuvant techniques for the management of large carotid body tumors. A case report and review. Cardiovasc Surg 1999;7:139-45.
31. Horowitz M, Whisnant RE, Jungreis C, Snyderman C, Levy EI, Kassam A. Temporary balloon occlusion and ethanol injection for preoperative embolization of carotid-body tumor. Ear Nose Throat J 2002;81:536-8. 540, 542 passim.
32. Puggioni A, Delis KT, Fields CE, Viozzi CF, Kallmes DF, Gloviczki P. Large symptomatic carotid body tumor resection aided by preoperative embolization and mandibular subluxation. Perspect Vasc Surg Endovasc Ther 2005;17:21-8.
33. Pecorari G, Roccia F, Nadalin J, Giordano C, Garzaro M. Combined endovascular and surgical treatment of carotid body tumor in a patient with thoracic situs solitus. Head Neck 2008;30:1523-6.
34. Siedek V, Waggershauser T, Berghaus A, Matthias C. Intraoperative monitoring of intraarterial paraganglioma embolization by indocyaningreen fluorescence angiography. Eur Arch Otorhinolaryngol 2009;266:1449-54.
35. Lim JY, Kim J, Kim SH, Lee S, Lim YC, Kim JW, et al. Surgical treatment of carotid body paragangliomas: outcomes and complications according to the Shamblin classification. Clin Exp Otorhinolaryngol 2010;3:91-5.
36. Wiegand S, Kureck I, Chapot R, Sesterhenn AM, Bien S, Werner JA. Early side effects after embolization of a carotid body tumor using Onyx. J Vasc Surg 2010;52:742-5.
37. Avgerinos ED, Moulakakis K, Brountzos E, Giannakopoulos TG, Lazaris AM, Koumarianou A, et al. Advances in assessment and management of carotid body tumors. Vascular 2011;19:250-6.
38. San Norberto EM, Taylor JH, Carrera S, Vaquero C. Intraoperative embolization with poloxamer 407 during surgical resection of a carotid body tumor. J Vasc Surg 2012;56:1782-5.
39. Cvjetko I, Erdelez L, Podvez Z, Buhin M, Vidjak V, Borovecki A, et al. Coil embolization and surgical removal of carotid body paraganglioma. J Craniofac Surg 2013;24:e242-5.
40. Wanke I, Jäckel MC, Goericke S, Panagiotopoulos V, Dietrich U, Forsting M. Percutaneous embolization of carotid paragangliomas using solely Onyx. AJNR Am J Neuroradiol 2009;30:1594-7.
41. Abdel-Aziz T, Lehmann M, Dietrich U, Ebmeyer J, Sudhoff H. Surgical outcome of carotid body tumour resection after percutaneous embolization using Onyx(®), an ethylene-vinyl alcohol copolymer. Head Neck Oncol 2013;5:5.
42. Liapis CD, Evangelidakis EL, Papavassiliou VG, Kakisis JD, Gougoulakis AG, Polyzos AK, et al. Role of malignancy and preoperative embolization in the management of carotid body tumors. World J Surg 2000;24:1526-30.
43. Karatas E, Sirikci A, Baglam T, Mumbuc S, Durucu C, Tutar E, et al. Synchronous bilateral carotid body tumor and vagal paraganglioma: a case report and review of literature. Auris Nasus Larynx 2008;35:171-5.
44. Alaraj A, Pytynia K, Carlson AP, Krishna PH, Charbel FT, Amin-Hanjani S, et al. Combined preoperative onyx embolization and protective internal carotid artery covered stent placement for treatment of

glomus vagale tumor: review of literature and illustrative case. Neurol Res 2012;34:523-9.

45. Westerband A, Hunter GC, Cintora I, Coulthard SW, Hinni ML, Gentile AT, et al. Current trends in the detection and management of carotid body tumors. J Vasc Surg 1998;28:84-92; discussion: 92-3.
46. Krishnamoorthy T, Gupta AK, Rajan JE, Thomas B. Stroke from delayed embolization of polymerized glue following percutaneous direct injection of a carotid body tumor. Korean J Radiol 2007;8:249-53.
47. Robison JG, Shagets FW, Beckett WC Jr, Spies JB. A multidisciplinary approach to reducing morbidity and operative blood loss during resection of carotid body tumor. Surg Gynecol Obstet 1989;168:166-70.
48. McLafferty BR. Preoperative embolization in managing carotid body tumors. Endovasc Today 2005:49-53.
49. Harman M, Etlik O, Unal O. Direct percutaneous embolization of a carotid body tumor with n-butyl cyanoacrylate: an alternative method to endovascular embolization. Acta Radiol 2004;45:646-8.

Submitted Aug 19, 2014; accepted Jan 19, 2015.

Additional material for this article may be found online at www.jvascsurg.org.

Supplementary Table (online only). List of related publications

Study ID	*Citation*
Schick, 1980	Schick PM, Hieshima GB, White RA, Fiaschetti FL, Mehringer CM, Grinnell VS, et al. Arterial catheter embolization followed by surgery for large chemodectoma. Surgery 1980;87:459-64.
Kumar, 1982	Kumar AJ, Kaufman SL, Patt J, Posey JB, Maxwell DD, White RI. Preoperative embolization of hypervascular head and neck neoplasms using microfibrillar collagen. AJNR Am J Neuroradiol 1982;3:163-8.
Borges, 1983	Borges LF, Heros RC, DeBrun G. Carotid body tumors managed with preoperative embolization. Report of two cases. J Neurosurg 1983;59:867-70.
Hennessy, 1984	Hennessy O, Jamieson CW, Allison DJ. Pre-operative embolisation of a chemodectoma. Br J Radiol 1984;57:845-6.
DuBois, 1987	DuBois J, Kelly W, McMenamin P, Macbeth GA. Bilateral carotid body tumors managed with preoperative embolization: a case report and review. J Vasc Surg 1987;5:648-50.
Ward, 1988	Ward PH, Liu C, Vinuela F, Bentson JR. Embolization: an adjunctive measure for removal of carotid body tumors. Laryngoscope 1988;98:1287-91.
Robison, 1989	Robison JG, Shagets FW, Beckett WC, Spies JB. A multidisciplinary approach to reducing morbidity and operative blood loss during resection of carotid body tumor. Surg Gynecol Obstet 1989;168:166-70.
LaMuraglia, 1992	LaMuraglia GM, Fabian RL, Brewster DC, Pile-Spellman J, Darling RC, Cambria RP, et al. The current surgical management of carotid body paragangliomas. J Vasc Surg 1992;15:1038-44; discussion: 1044-5.
Fruhwirth, 1996	Fruhwirth J, Koch G, Hauser H, Gutschi S, Beham A, Kainz J. Paragangliomas of the carotid bifurcation: oncological aspects of vascular surgery. Eur J Surg Oncol 1996;22:88-92.
Litle, 1996	Litle VR, Reilly LM, Ramos TK. Preoperative embolization of carotid body tumors: when is it appropriate? Ann Vasc Surg 1996;10:464-8.
Muhm, 1997	Muhm M, Polterauer P, Gstöttner W, Temmel A, Richling B, Undt G, et al. Diagnostic and therapeutic approaches to carotid body tumors. Review of 24 patients. Arch Surg 1997;132:279-84.
Westerband, 1998	Westerband A, Hunter GC, Cintora I, Coulthard SW, Hinni ML, Gentile AT, et al. Current trends in the detection and management of carotid body tumors. J Vasc Surg 1998;28:84-92; discussion: 92-3.
Iafrati, 1999	Iafrati MD, O'Donnell TF. Adjuvant techniques for the management of large carotid body tumors. A case report and review. Cardiovasc Surg 1999;7:139-45.
Liapis, 2000	Liapis CD, Evangelidakis EL, Papavassiliou VG, Kakisis JD, Gougoulakis AG, Polyzos AK, et al. Role of malignancy and preoperative embolization in the management of carotid body tumors. World J Surg 2000;24:1526-30.
Kafie, 2001	Kafie FE, Freischlag JA. Carotid body tumors: the role of preoperative embolization. Ann Vasc Surg 2001;15:237-42.
Horowitz, 2002	Horowitz M, Whisnant RE, Jungreis C, Snyderman C, Levy EI, Kassam A. Temporary balloon occlusion and ethanol injection for preoperative embolization of carotid-body tumor. Ear Nose Throat J 2002;81:536-8, 540, 542 passim.
Persky, 2002	Persky MS, Setton A, Niimi Y, Hartman J, Frank D, Berenstein A. Combined endovascular and surgical treatment of head and neck paragangliomas—a team approach. Head Neck 2002;24:423-31.
Yilmaz, 2003	Yilmaz S, Sindel T, Luleci E, Tuncar R. Preoperative embolization of carotid body tumors with microsphere particles. Ann Vasc Surg 2003;17:697-698; author reply: 698.
Abud, 2004	Abud DG, Mounayer C, Benndorf G, Piotin M, Spelle L, Moret J. Intratumoral injection of cyanoacrylate glue in head and neck paragangliomas. AJNR Am J Neuroradiol 2004;25:1457-62.
Harman, 2004	Harman M, Etlik O, Unal O. Direct percutaneous embolization of a carotid body tumor with n-butyl cyanoacrylate: an alternative method to endovascular embolization. Acta Radiol 2004;45:646-8.
Tasar, 2004	Tasar M, Yetiser S. Glomus tumors: therapeutic role of selective embolization. J Craniofac Surg 2004;15:497-505.
Puggioni, 2005	Puggioni A, Delis KT, Fields CE, Viozzi CF, Kallmes DF, Gloviczki P. Large symptomatic carotid body tumor resection aided by preoperative embolization and mandibular subluxation. Perspect Vasc Surg Endovasc Ther 2005;17:21-8.
Antonitsis, 2006	Antonitsis P, Saratzis N, Velissaris I, Lazaridis I, Melas N, Ginis G, et al. Management of cervical paragangliomas: review of a 15-year experience. Langenbecks Arch Surg 2006;391:396-402.
Kollert, 2006	Kollert M, Minovi AA, Draf W, Bockmühl U. Cervical paragangliomas-tumor control and long-term functional results after surgery. Skull Base 2006;16:185-91.
Singh, 2006	Singh D, Pinjala RK, Reddy RC, Satya Vani PV. Management for carotid body paragangliomas. Interact Cardiovasc Thorac Surg 2006;5:692-5.
Kasper, 2007	Kasper GC, Welling RE, Wladis AR, CaJacob DE, Grisham AD, Tomsick TA, et al. A multidisciplinary approach to carotid paragangliomas. Vasc Endovasc Surg 2006;40:467-74.
Krishnamoorthy, 2007	Krishnamoorthy T, Gupta AK, Rajan JE, Thomas B. Stroke from delayed embolization of polymerized glue following percutaneous direct injection of a carotid body tumor. Korean J Radiol 2007;8:249-53.
Karatas, 2008	Karatas E, Sirikci A, Baglam T, Mumbuc S, Durucu C, Tutar E, et al. Synchronous bilateral carotid body tumor and vagal paraganglioma: a case report and review of literature. Auris Nasus Larynx 2008;35:171-5.
Pecorari, 2008	Pecorari G, Roccia F, Nadalin J, Giordano C, Garzaro M. Combined endovascular and surgical treatment of carotid body tumor in a patient with thoracic situs solitus. Head Neck 2008;30:1523-6.
Siedek, 2008	Siedek V, Waggershauser T, Berghaus A, Matthias C. Intraoperative monitoring of intraarterial paraganglioma embolization by indocyaningreen fluorescence angiography. Eur Arch Otorhinolaryngol 2009;266:1449-54.
Elhammady, 2009	Elhammady MS, Farhat H, Ziayee H, Aziz-Sultan MA. Direct percutaneous embolization of a carotid body tumor with Onyx. J Neurosurg 2009;110:124-7.
Karaman, 2009	Karaman E, Isildak H, Yilmaz M, Edizer DT, Ibrahimov M, Cansiz H, et al. Management of paragangliomas in otolaryngology practice: review of a 7-year experience. J Craniofac Surg 2009;20:1294-7.
Martinelly, 2009	Martinelli O, Irace L, Massa R, Savelli S, Giannoni F, Gattuso R, et al. Carotid body tumors: radioguided surgical approach. J Exp Clin Cancer Res 2009;28:148.

Supplementary Table (online only). Continued.

Study ID	*Citation*
Siedek, 2009	Siedek V, Waggershauser T, Berghaus A, Matthias C. Intraoperative monitoring of intraarterial paraganglioma embolization by indocyaningreen fluorescence angiography. Eur Arch Otorhinolaryngol 2009;266:1449-54.
Vogel, 2009	Vogel TR, Mousa AY, Dombrovskiy VY, Haser PB, Graham AM. Carotid body tumor surgery: management and outcomes in the nation. Vasc Endovascular Surg 2009;43:457-61.
Wanke, 2009	Wanke I, Jäckel MC, Goericke S, Panagiotopoulos V, Dietrich U, Forsting M. Percutaneous embolization of carotid paragangliomas using solely Onyx. AJNR Am J Neuroradiol 2009;30:1594-7.
Zeitler, 2009	Zeitler DM, Glick J, Har-El G. Preoperative embolization in carotid body tumor surgery: is it required? Ann Otol Rhinol Laryngol 2010;119:279-83.
Hall, 2010	Hall TC, Renwick P, Stafford ND. Recurrent familial malignant carotid body tumour presenting with lymph node metastasis: case report, and review of diagnosis and management of familial carotid body tumours. J Laryngol Otol 2010;124:1344-6.
Li, 2010	Li J, Wang S, Zee C, Yang J, Chen W, Zhuang W, et al. Preoperative angiography and transarterial embolization in the management of carotid body tumor: a single-center, 10-year experience. Neurosurgery 2010;67:941-8; discussion: 948.
Lim, 2010	Lim JY, Kim J, Kim SH, Lee S, Lim YC, Kim JW, et al. Surgical treatment of carotid body paragangliomas: outcomes and complications according to the Shamblin classification. Clin Exp Otorhinolaryngol 2010;3:91-5.
Ozyer, 2010	Ozyer U, Harman A, Yildirim E, Aytekin C, Akay TH, Boyvat F. Devascularization of head and neck paragangliomas by direct percutaneous embolization. Cardiovasc Intervent Radiol 2010;33:967-5.
Wiegand, 2010	Wiegand S, Kureck I, Chapot R, Sesterhenn AM, Bien S, Werner JA. Early side effects after embolization of a carotid body tumor using Onyx. J Vasc Surg 2010;52:742-5.
Avgerinos, 2011	Avgerinos ED, Moulakakis K, Brountzos E, Giannakopoulos TG, Lazaris AM, Koumarianou A, et al. Advances in assessment and management of carotid body tumors. Vascular 2011;19:250-6.
Fennessy, 2011	Fennessy BG, Kozakewich HP, Silvera M, Frerichs K, Lillhei CW, Poe D, et al. The presentation and management of multiple paraganglioma in head and neck. Ir J Med Sci 2011;180:757-60.
Gemmete, 2011	Gemmete JJ, Pandey AS, Chaudhary N, Potti TA. Paradoxical embolus to the brain from embolization of a carotid body tumor. J Neurointerv Surg 2012;4:e12.
Gwon, 2011	Gwon JG, Kwon TW, Kim H, Cho YP. Risk factors for stroke during surgery for carotid body tumors. World J Surg 2011;35:2154-8.
Sahin, 2011	Sahin MA, Jahollari A, Guler A, Doganci S, Bingol H, Karaman B, et al. Results of combined preoperative direct percutaneous embolization and surgical excision in treatment of carotid body tumors. Vasa 2011;40:461-6.
Shah, 2011	Shah HM, Gemmete JJ, Chaudhary N, Pandey AS, Ansari SA. Preliminary experience with the percutaneous embolization of paragangliomas at the carotid bifurcation using only ethylene vinyl alcohol copolymer (EVOH) Onyx. J Neurointerv Surg 2012;4:125-9.
Yang, 2011	Yang TH, Ou CH, Yang MS, Lee YC, Yeh LR. Preoperative embolization of carotid body tumor by direct percutaneous intratumoral injection of N-butyl cyanoacrylate glue assisted with balloon protection technique. J Chin Med Assoc 2011;74:91-4.
Alaraj, 2012	Alaraj A, Pytynia K, Carlson AP, Krishna PH, Charbel FT, Amin-Hanjani S, et al. Combined preoperative onyx embolization and protective internal carotid artery covered stent placement for treatment of glomus vagale tumor: review of literature and illustrative case. Neurol Res 2012;34:523-9.
Elhammady, 2012	Elhammady MS, Peterson EC, Johnson JN, Aziz-Sultan MA. Preoperative onyx embolization of vascular head and neck tumors by direct puncture. World Neurosurg 2012;77:725-30.
Nazari, 2012	Nazari I, Aarabi Moghaddam F, Zamani MM, Salimi J. Clinical characteristics and remedies in 45 Iranians with carotid body tumors. Acta Med Iran 2012;50:339-43.
Power, 2012	Power AH, Bower TC, Kasperbauer J, Link MJ, Oderich G, Cloft H, et al. Impact of preoperative embolization on outcomes of carotid body tumor resections. J Vasc Surg 2012;56:979-89.
San Roberto, 2012	San Norberto EM, Taylor JH, Carrera S, Vaquero C. Intraoperative embolization with poloxamer 407 during surgical resection of a carotid body tumor. J Vasc Surg 2012;56:1782-5.
Zhang, 2012	Zhang TH, Jiang WL, Li YL, Li B, Yamakawa T. Perioperative approach in the surgical management of carotid body tumors. Ann Vasc Surg 2012;26:775-82.
Abdel-Aziz, 2013	Abdel-Aziz T, Lehmann M, Dietrich U, Ebmeyer J, Sudhoff H. Surgical outcome of carotid body tumour resection after percutaneous embolization using Onyx(®), an ethylene-vinyl alcohol copolymer. Head Neck Oncol 2013;5:5.
Cvjetko, 2013	Cvjetko I, Erdelez L, Podvez Z, Buhin M, Vidjak V, Borovecki A, et al. Coil embolization and surgical removal of carotid body paraganglioma. J Craniofac Surg 2013;24:e242-245.
Fruhmann, 2013	Fruhmann J, Geigl JB, Konstantiniuk P, Cohnert TU. Paraganglioma of the carotid body: treatment strategy and SDH-gene mutations. Eur J Vasc Endovasc Surg 2013;45:431-6.
Sen, 2013	Sen I, Stephen E, Malepathi K, Agarwal S, Shyamkumar NK, Mammen S. Neurological complications in carotid body tumors: a 6-year single-center experience. J Vasc Surg 2013;57:64-8S.
Kalani, 2013	Kalani MY, Ducruet AF, Crowley RW, Spetzler RF, McDougall CG, Albuquerque FC. Transfemoral transarterial onyx embolization of carotid body paragangliomas: technical considerations, results, and strategies for complication avoidance. Neurosurgery 2013;72:9-15; discussion: 15.