

# Heparin versus bivalirudin for carotid artery stenting using proximal endovascular clamping for neuroprotection: Results from a prospective randomized study

Eugenio Stabile, MD, PhD,<sup>a</sup> Giovanni Sorropago, MD,<sup>a</sup> Tullio Tesorio, MD,<sup>a</sup> Grigore Popusoi, MD,<sup>a</sup> Vittorio Ambrosini, MD,<sup>a</sup> Maria Teresa Mottola, MD,<sup>b</sup> Giancarlo Biamino, MD,<sup>a</sup> and Paolo Rubino, MD,<sup>a</sup> *Mercogliano, Italy*

**Background:** General recommendations indicate that, during a carotid artery stenting (CAS), sufficient unfractionated heparin (UFH) has to be given to maintain the activated clotting time between 250 to 300 seconds. Bivalirudin use is able to reduce postprocedural bleedings in percutaneous interventions when compared with UFH. The study purpose was to evaluate, in a randomized study, the safety and efficacy of bivalirudin versus heparin during CAS, using proximal endovascular occlusion (PEO) as a distal protection device.

**Methods:** From January 2006 to December 2009, 220 patients undergoing CAS using PEO have been randomly assigned to one of the study arms (control arm: 100 UI/kg UFH or bivalirudin arm: 0.75 mg/kg intravenous bolus and intraprocedural infusion at 1.75 mg/kg/h).

**Results:** Procedural success was achieved in all the patients. No episodes of intraprocedural thrombosis occurred. One major stroke occurred in the bivalirudin arm, and two minor strokes occurred, one in each group. A significant difference in the incidence of postprocedural bleedings was observed between the study groups; bivalirudin use was associated with reduced number of bleedings according to Thrombolysis In Myocardial Infarction criteria.

**Conclusions:** The use of bivalirudin should be considered a safe and effective anticoagulation regimen during CAS, using PEO as a distal protection device. Bivalirudin use is associated with a reduced incidence of bleedings. (*J Vasc Surg* 2010; 52:1505-10.)

The role of carotid artery stenting (CAS) as a possible alternative to carotid endarterectomy (CEA), particularly in patients at high risk for CEA,<sup>1</sup> is being evaluated. Unfractionated heparin (UFH) remains the most commonly used agent during percutaneous CAS.<sup>2</sup> Significant debate remains, however, with regard to the correlation between the effects of UFH and ensuing ischemic and hemorrhagic complications.<sup>3,4</sup> Bivalirudin has been evaluated as an alternative to heparin in patients undergoing percutaneous coronary interventions and proved to reduce the risk of bleeding complications.<sup>5,6</sup> The use of bivalirudin has been suggested for CAS procedures.<sup>7,8</sup> Potential advantages of bivalirudin use include lower bleeding risk, no need for activated clotting time (ACT) monitoring,<sup>9</sup> and safe use in patients with heparin-induced thrombocytopenia.<sup>10</sup> In this study, we evaluated, in a randomized prospective study, safety and efficacy of bivalirudin versus heparin during

CAS, using proximal endovascular occlusion (PEO) for neuroprotection.

## METHODS

**Patient selection.** From January 2007 to December 2009, 915 consecutive patients underwent CAS at our institution. Of these, 868 CAS were performed using PEO for neuroprotection. Among the PEO-protected CAS, 220 were enrolled in the study.

Inclusion criteria was the stenosis grade determined based on Echo Duplex Scanner and preoperative angiography:<sup>11,12</sup>

- 1) symptomatic stenosis of the internal carotid artery (ICA)  $\geq 50\%$ ;
- 2) asymptomatic stenosis  $\geq 80\%$ .

Patients with the following criteria were excluded:

- 1) emergency percutaneous carotid intervention;
- 2)  $>90$  years old;
- 3) low-molecular-weight heparin within  $<12$  hours, or warfarin within  $<3$  days;
- 4) an international normalized ratio  $>1.3$ ;
- 5) an indication for long-term anticoagulation;
- 6) contraindication to aspirin or thienopyridines;
- 7) severe renal dysfunction (creatinine clearance  $<30$  mL/min);
- 8) refused informed consent before enrollment.

From the Invasive Cardiology Laboratory, Cardiology Division, Clinica Montevergine;<sup>a</sup> Laboratory of Clinical Diagnostic, Clinica Montevergine.<sup>b</sup>

Competition of interest: none.

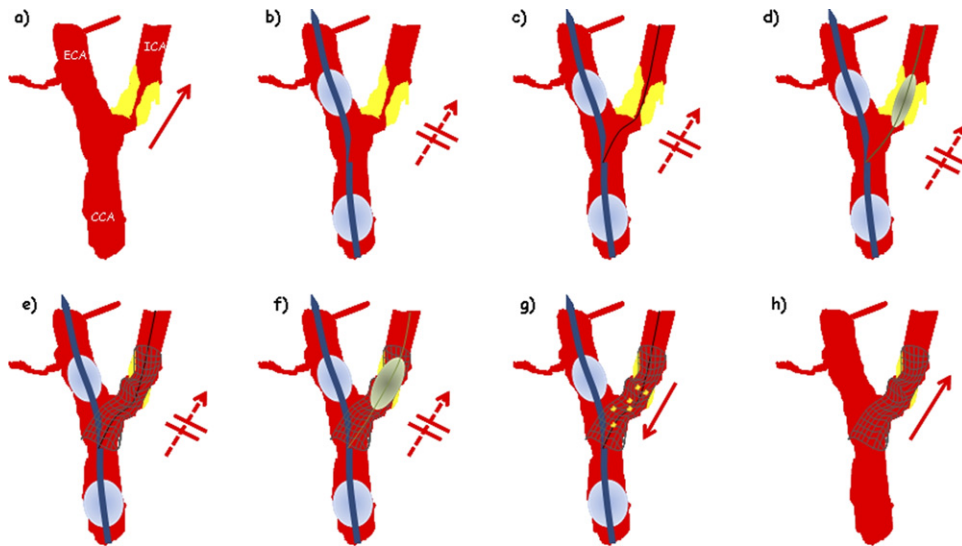
Reprint requests: Eugenio Stabile, MD, PhD, Invasive Cardiology Laboratory, Cardiology Division, Clinica Montevergine, Mercogliano, Italy (e-mail: geko50@hotmail.com).

The editors and reviewers of this article have no relevant financial relationships to disclose per the JVS policy that requires reviewers to decline review of any manuscript for which they may have a competition of interest.

0741-5214/\$36.00

Copyright © 2010 by the Society for Vascular Surgery.

doi:10.1016/j.jvs.2010.06.098



**Fig 1.** Schematic representation of carotid artery stenting performed with proximal endovascular occlusion for neuroprotection. (a) Schematic representation of carotid bifurcation (CCA, common carotid artery; ECA, external carotid artery; ICA, internal carotid artery). An atherosclerotic plaque determines severe stenosis at the ostium of the ICA (red arrow indicates flow direction). (b) The system for proximal endovascular occlusion (PEO) is advanced till the distal balloon is located in the ECA, around 1 cm beyond bifurcation. Then the distal balloon is inflated in the ECA and the proximal balloon in the CCA, thus blocking the antegrade and the retrograde flow across the ICA. (c) A 0.014" wire is then navigated through the ICA stenosis under proximal protection. (d) Plaque predilation is performed, using a balloon catheter, under proximal protection. (e) A self-expanding carotid stents is deployed from the proximal ICA to the distal CCA. (f) Postdilation is performed, using a balloon catheter, under proximal protection. (g) After postdilation, at least 60 mL of blood was aspirated and filtered through sieves, checking for visible plaque debris. Blood flow was restored only after three consecutive aspirations free of debris, deflating first the distal balloon and then the proximal balloon. (h) The system for PEO is removed, and the artery is free of residual stenosis.

The human ethics committee of the Clinica Montevergine provided approval for the study.

**Concomitant therapy.** Patients received aspirin (75-160 mg/day), and should have been on ticlopidine therapy (250 mg twice daily) for at least 7 days. Alternatively, patients received clopidogrel preload (300 mg) 24 hours before procedure. Postprocedure, the same thienopyridine (either ticlopidine or clopidogrel) was continued for 3 months, whereas aspirin was continued for life.

**Study arms.** Patients were electronically randomly assigned one to one to each of the study arms (110 patients per arm).

- 1) Control arm: 70 to 100 UI/kg heparin before wiring the external carotid artery, with the intention of achieving ACT >250 seconds during the carotid intervention. Additional heparin was administered at operator discretion according to ACT values.<sup>2</sup>
- 2) Bivalirudin arm: 0.75 mg/kg intravenous (IV) bolus of bivalirudin, before wiring the external carotid artery, (Angiomax; The Medicines Company, New York, NY) followed by infusion at a rate of 1.75 mg/kg/hr (1.4 mg/kg/hr if creatinine clearance <60 mL/hr). At the completion of the carotid stenting procedure, IV bivalirudin was discontinued.<sup>9</sup>

## TECHNIQUE OF THE CAS PROCEDURE

All CAS procedures were performed under local anesthesia by physicians fulfilling qualifications defined by the Italian Consensus Carotid Stenting - Stroke Prevention and Educational Awareness Diffusion Joint Committee.<sup>13</sup>

During the intervention, an anesthesiologist monitored hemodynamic parameters and neurological status. At procedure start, an 8- to 10-Fr, 25-cm-long introducer sheath (Terumo, Tokyo, Japan) was inserted in the abdominal aorta via the common femoral artery. A selective coronary angiogram, an aortic arch angiography, and elective bilateral carotid artery catheterization was performed in all patients prior to CAS.<sup>1</sup>

Once the diagnostic angiogram was completed, the neuroprotection system (Mo.Ma system, Invatec, Roncadelle, Italy) was positioned in the distal external carotid artery (ECA; Fig 1).<sup>14-17</sup> At this point, the distal balloon was inflated in the ECA and the proximal balloon in the common carotid artery (CCA), thus establishing neuroprotection. A 0.014" guidewire was then navigated through the lesion. A predilation of the internal carotid artery (ICA) lesion was left at the operator's discretion. In all cases, self-expanding carotid stents were deployed using a rapid-exchange technique.

**Table I.** Bleeding definitions based on Thrombolysis In Myocardial Infarction (TIMI) criteria

Definition	Criteria
Major	Patient had hemorrhagic stroke or a hematocrit decreased by 15 points or by 10 to 15 points with clinical bleeding.
Minor	Patient had a hematocrit decreased by <10 points with clinical bleeding or by 10 to 15 points without clinical bleeding. No bleeding was defined as a hematocrit decrease of <10 points with no clinical bleeding.
Clinical bleeding	Patient had a large hematoma (a palpable swelling of 4 cm at the site of vascular access) or gastrointestinal blood loss (gross hematemesis, heme-positive coffee ground emesis, or heme-positive melena), or retroperitoneal bleeding.

After a mandatory postdilation, at least 60 mL of blood was aspirated and filtered through sieves to collect particulate plaque debris. Blood flow was restored after three consecutive aspirations free of debris. The final angiography included ipsilateral biplane carotid and intracranial views.

Occlusion time was defined as the time lasting from the inflation to the deflation of the proximal balloon in the CCA.<sup>14-17</sup> Occlusion intolerance was defined as a transient neurological deficit observed during the clamping time; however, showing a complete recovery within 20 minutes after restoring the antegrade flow. In the absence of a complete recovery, the intolerance is considered a neurologic deficit.<sup>14-17</sup> Procedure time was defined as the amount of the time lasting from completion of diagnostic angiography to the final intracranial views acquisition.

**Postprocedural patient management.** Femoral sheaths were removed when the ACT was <150 seconds in the heparin group and 2 hours postprocedure, independently of ACT values, in the bivalirudin group; this was because the anticoagulative effect is completely reversed 1 hour after bivalirudin discontinuation.<sup>18</sup> Access site hemostasis was achieved through manual compression in all patients.

If clinical signs of limb ischemia occurred on the side of femoral access, sheaths were removed independently of postprocedural time and ACT values. Femoral sheath-induced leg ischemia was classified as major if thromboembolotomy was required and minor if resolved by sheath removal.<sup>19</sup>

A complete blood count and independent neurological evaluation was obtained before CAS procedure and prior to hospital discharge.<sup>14</sup>

## DEFINITIONS

The primary endpoint of this study was safety, defined as:

- 1) absence of intraprocedural thrombotic or hemorrhagic complications;
- 2) 30-day death and cumulative stroke rate. Neurological complications were classified as one of the following: minor stroke defined as a new neurological deficit that either resolves completely within 30 days or increased National Institute of Health Stroke scale (NIHSS) by  $\leq 3$ ; major stroke defined as a new neurological deficit that persists for >30 days and increased NIHSS by  $\geq 4$ .<sup>19,20</sup>

Secondary endpoints were:

- 1) procedural success, defined as completion of the CAS procedure using the Mo.Ma endovascular clamping technique, achieving <30% residual stenosis after successful CAS;
- 2) postprocedural bleedings. Bleeding definitions were based on Thrombolysis In Myocardial Infarction (TIMI) criteria (Table I)<sup>21</sup> and were classified as major if the patient had hemorrhagic stroke or if hematocrit decreased by 15 points or by 10 to 15 points with clinical bleeding. Bleeding was classified as minor if hematocrit decreased by <10 points with clinical bleeding or by 10 to 15 points without clinical bleeding. No bleeding was defined as a hematocrit decrease of <10 points with no clinical bleeding. Clinical bleeding is defined as (1) a large hematoma (a palpable swelling of 4 cm at the site of vascular access); (2) gastrointestinal blood loss (gross hematemesis, heme-positive coffee ground emesis, or heme-positive melena); or (3) retroperitoneal bleeding.

**Follow-up.** All patients were followed up at 1 month after percutaneous transluminal angioplasty with a clinical examination assessing overall general conditions, neurological symptoms, medication, and hospitalizations after the CAS procedure.<sup>14</sup>

**Statistics.** Continuous variables between groups were compared by *t* test for normally distributed values. Proportions were compared by  $\chi^2$  or Fisher exact tests, where appropriate. Results are expressed as mean  $\pm$  SD or n (%) unless otherwise specified. A two-tailed probability value <.05 was considered statistically significant for superiority analysis, and a one-tailed probability value <0.05 was considered statistically significant for noninferiority analysis.<sup>22</sup>

## RESULTS

Patients' demographic characteristics are presented in Table II. Both groups presented similar incidence of atherosclerosis risk factors, concomitant coronary artery disease, and chronic renal failure. Procedure-related characteristics are presented in Table III. The rate of symptomatic patients was similar in both groups. Both therapeutic regimens provided adequate anticoagulation, and no catheter/device thrombosis occurred in each of the groups.

Procedural success was equal between the groups (100%). Clamping intolerance was observed in 38 patients; in all cases, CAS could be concluded under cerebral protection and neurological symptoms resolved within 20

**Table II.** Patients' demographic characteristics

	Bivalirudin	Unfractionated heparin	P value
Number of patients	110	110	NS
Male (%) (n)	73.7 (81)	71.8 (79)	NS
Age (yr)	69.9 ± 7.8	70.6 ± 8.8	NS
Smoke history (%) (n)	86.9 (94)	89.9 (100)	NS
Diabetes (%) (n)	31.1 (34)	40.0 (66)	NS
Hypertension (%) (n)	78.8 (87)	84.5 (93)	NS
Hypercholesterolemia (%) (n)	72.7 (80)	62.7 (69)	NS
Creatinine clearance >30 <60 mL-min (%) (n)	30.3 (33)	31.8 (35)	NS
Presence of significant coronary artery disease (%) (n)	68.7 (76)	65.0 (72)	NS
Symptomatic patients (%) (n)	18.2 (20)	17.2 (19)	NS

*Hypercholesterolemia*, serum low-density lipoprotein >130 mg/dL; *Symptomatic patients*, patients who suffered a transient ischemic attack or a stroke in the previous 6 months.

**Table III.** Procedural characteristics

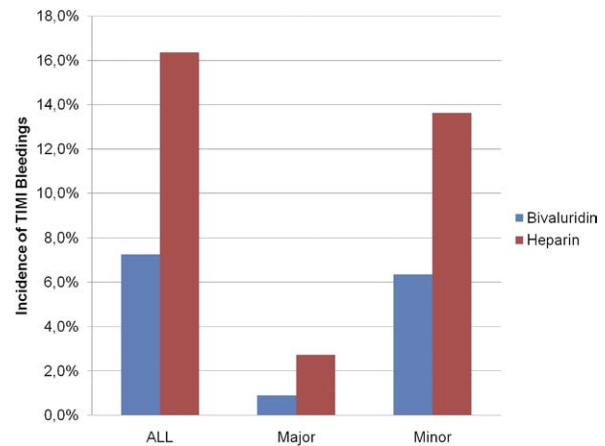
	Bivalirudin	Heparin	P value
Pts #	110	110	NS
Contralateral ICA stenosis >80% (%) (n)	6.7 (7)	9.1 (10)	NS
Contralateral ICA occlusion (%) (n)	10.0 (11)	14.5 (16)	NS
Predilation (%) (n)	53.5 (59)	44.5 (49)	NS
Type of stent (%) (n)			
Stainless steel	0 (0)	0.9 (1)	
Open cells nitinol	8.1 (9)	13.6 (15)	
Closed cells nitinol	60.9 (67)	60.9 (67)	
Hybrid cells nitinol	31.3 (34)	24.5 (27)	
Procedure time (min)	18 ± 7	19 ± 6	NS
Clamping time (sec)	222 ± 72	219 ± 73	NS
Clamping intolerance (%) (n)	16.4 (18)	18.1 (20)	NS
Sheath size (%) (n)			NS
10	30.9 (34)	30 (33)	
9	55.5 (61)	53.6 (59)	
8	13.6 (15)	16.4 (18)	

ICA, Internal carotid artery.

minutes after proximal balloon deflation. Similar incidence of balloon predilatation and specific stent use was observed among the groups.

During in-hospital stay, no patients died, one had a major stroke, and two patients had a minor stroke. Of these, one patient, in the bivalirudin group, had a hyperperfusion syndrome that ultimately resulted in a major hemorrhagic stroke the day following the procedure.

One patient in the bivalirudin group had a minor stroke manifesting a hemiparesis 4 hours after CAS; symptoms relieved completely within 3 days, and the patient was dismissed at home. Another patient, in the heparin group, had a left-hand paresis that resolved 2 days following the intervention. Overall, 30-day death and stroke rate was 1.36%. Despite the presence of coronary artery disease in nearly 70% of the patients, no myocardial infarction occurred.



**Fig 2.** Postprocedural TIMI bleeding. Bar graph representing incidence of postprocedural TIMI bleeding. Bivalirudin use reduced the incidence of postprocedural bleeding (All = Major + Minor,  $P < .05$ ; Major,  $P = .31$ ; Minor,  $P = .07$ ).

Among the bleeding events (Fig 2), eight patients in the heparin group and 18 patients in the bivalirudin had a bleeding event according to TIMI criteria. Of these, one patient in the bivalirudin group had major bleeding as did three patients in the heparin group. Among minor bleedings, there were seven in the bivalirudin group and 15 in the heparin group. All TIMI major bleedings prolonged in-hospital stay, but none of them resulted in hemodynamic compromise or required blood transfusion. None of the TIMI minor bleedings prolonged in-hospital stay or resulted in hemodynamic compromise or required blood transfusion.

In two patients (heparin group), the sheath had to be removed early because of signs of leg ischemia; early sheath removal resolved symptoms and was not associated with an increased incidence of bleeding.

Sheath size influenced bleeding rate. Bleedings were significantly lower when smaller sheaths were used (Figs 3 and 4). The beneficial effect of bivalirudin use was more evident when a larger sheath was used (Figs 3 and 4). During the 30-day follow-up, no major adverse cardiac and cerebrovascular events (MACCE) occurred.

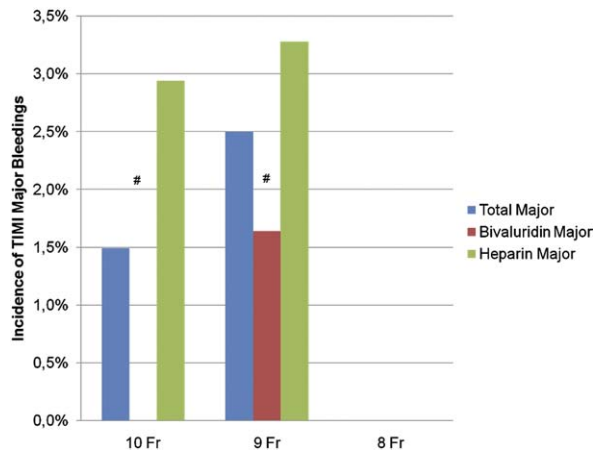
## DISCUSSION

The results of this study confirmed that:

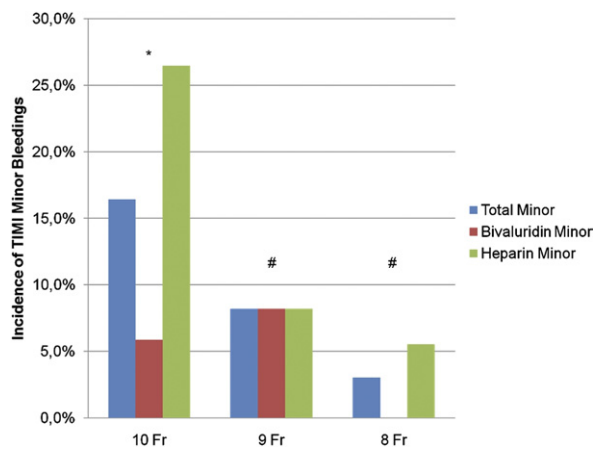
- carotid artery stenting, with the use of endovascular clamping as a neuroprotection device, is a safe and efficient procedure, which can be safely performed using bivalirudin;
- bivalirudin use is associated with a significant lower bleeding rate.

UFH remains the most commonly used agent during percutaneous CAS.<sup>2</sup> Bivalirudin has been evaluated as an alternative to heparin in patients undergoing percutaneous coronary intervention and proved to reduce postprocedural





**Fig 3.** Postprocedural TIMI major bleeding according to femoral sheath size. Bar graph representing incidence of postprocedural TIMI bleeding. A reduced incidence of postprocedural bleeding can be observed when a 10 or 9 French (Fr) sheath is used (#,  $P = ns$ ). No major bleeding was observed when procedures were performed using an 8 Fr sheath.



**Fig 4.** Postprocedural TIMI minor bleeding according to femoral sheath size. Bar graphic representing incidence of postprocedural TIMI minor bleeding. Bivalirudin use reduced the incidence of postprocedural bleeding when a 10 French (Fr) is used (\*,  $P = .02$ ). No difference can be observed when a 9 or an 8 Fr system is used (#,  $P = ns$ ).

bleedings.<sup>9</sup> The extent of bleeding and major vascular complications after CAS is reported in the major trials and ranged from 1.0 % to 3.1%.<sup>23,24</sup>

In a recent registry of a single-center experience of CAS with neuroprotection, the modification of the anticoagulation regimen (from UFH to bivalirudin) resulted in a significant decrease in hemorrhagic complications, which occurred in 6% in the UFH-treated and 1% in the bivalirudin-treated patients,<sup>7</sup> data confirmed in a recently reported single-center registry.<sup>8</sup> Consequently, bivalirudin use is permitted in ongoing CAS trials, but data in randomized studies are still lacking.

In this study, which is the first randomized trial testing bivalirudin use for CAS, bivalirudin use did not increase the MACCE rate and catheter/device thrombosis but reduced incidence of bleeding, according to TIMI criteria.

Despite the fact that relatively large sheaths (8 to 10 Fr) were used, all access sites hemostasis were obtained through a manual compression, none of the bleeding complications required transfusion or caused hemodynamic compromise. Only TIMI major bleeding prolonged in-hospital stay.

Of note is the fact that, as already reported,<sup>25</sup> the presence of a contralateral internal carotid artery stenosis or even an occlusion did not preclude the use of proximal endovascular occlusions and was not associated with an increased postprocedural event rate.

On the basis of our results, bivalirudin use, during endovascular clamping neuroprotected CAS procedures, reduces the incidence of minor bleeding when compared with heparin use. These data could be important in selecting a patient-tailored anticoagulation strategy. Because bivalirudin is much more expensive than heparin, the cost issue is very real.

UFH is a safe and efficient anticoagulation strategy, which should still be considered as the default therapy for the vast majority of the patients. In those patients with heparin-induced thrombocytopenia history or at high risk of bleeding, bivalirudin could be considered as a therapeutic alternative, when officially approved for CAS.

## AUTHOR CONTRIBUTIONS

Conception and design: ES  
Analysis and interpretation: TT, GS, MM  
Data collection: TT, GS, MM  
Writing the article: VA, GP  
Critical revision of the article: ES  
Final approval of the article: GB, PR  
Statistical analysis: VA, GP  
Obtained funding: PR  
Overall responsibility: PR

## REFERENCES

1. Yadav JS, Wholey MH, Kuntz RE, Fayad P, Katzen BT, Mishkel GJ, et al; Stenting and Angioplasty with Protection in Patients at High Risk for Endarterectomy Investigators. Protected carotid-artery stenting versus endarterectomy in high-risk patients. *N Engl J Med* 2004;351:1493-501.
2. Bates ER, Babb JD, Casey DE Jr, Cates CU, Duckwiler GR, Feldman TE, et al. ACCF/SCAI/SVMB/SIR/ASITN 2007 clinical expert consensus document on carotid stenting: a report of the American College of Cardiology Foundation Task Force on Clinical Expert Consensus Documents. *J Am Coll Cardiol* 2007;49:126-70.
3. Young E, Podor TJ, Venner T, Hirsh J. Induction of acute phase reaction increases heparin-binding proteins in plasma. *Arterioscler Thromb Vasc Biol* 1997;17:1568-74.
4. Hirsh J, Anand SS, Halperin JL, Fuster V. Guide to anticoagulant therapy: heparin. A statement for health care professionals from the American Heart Association. *Circulation* 2001;103:2994-3018.
5. Lincoff AM, Kleiman NS, Kereiakes DJ, Feit F, Bittl JA, Jackman JD, et al. Long-term efficacy of bivalirudin and provisional glycoprotein IIb/IIIa blockade vs heparin and planned glycoprotein IIb/IIIa blockade

- during percutaneous coronary revascularization: REPLACE-2 randomized trial. *JAMA* 2004;292:696-703.
6. Stone GW, McLaurin BT, Cox DA, Bertrand ME, Lincoff AM, Moses JW, et al. Bivalirudin for patients with acute coronary syndromes. *N Engl J Med* 2006;355:2203-16.
  7. Bush RL, Lin PH, Mureebe L, Zhou W, Peden EK, Lumsden AB. Routine bivalirudin use in percutaneous carotid interventions. *J Endovasc Ther* 2005;12:521-2.
  8. Schneider LM, Polena S, Roubin G, Iyer S, Vitek J, Panagopoulos G, et al. Carotid stenting and bivalirudin with and without vascular closure: 3-year analysis of procedural outcomes. *Catheter Cardiovasc Interv* 2010;75:420-6.
  9. Kastrati A, Neumann FJ, Mehilli J, Byrne RA, Iijima R, Büttner HJ, et al. Bivalirudin versus unfractionated heparin during percutaneous coronary intervention. *N Engl J Med* 2008;359:688-96.
  10. Warkentin TE, Greinacher A, Koster A, Lincoff AM. Treatment and prevention of heparin-induced thrombocytopenia: American College of Chest Physicians Evidence-Based Clinical Practice Guidelines. *Chest* 2008;133:340S-380S.
  11. North American Symptomatic Carotid Endarterectomy Trial collaborators. Beneficial effect of carotid endarterectomy in symptomatic patients with high-grade carotid stenosis. *N Engl J Med* 1991;325:445-53.
  12. Halliday A, Mansfield A, Marro J, Peto C, Peto R, Potter J, et al. Prevention of disabling and fatal strokes by successful carotid endarterectomy in patients without recent neurological symptoms: randomized controlled trial. *Lancet* 2004;363:1491-502.
  13. Cremonesi A, Setacci C, Bignamini A, Bolognese L, Briganti F, Di Sciascio G, et al. Carotid artery stenting: first consensus document of the ICCS-SPREAD Joint Committee. *Stroke* 2006;37:2400-9.
  14. Stabile E, Sorropago G, Tesorio T, Salemme L, Ambrosini V, Cioppa A, et al. Use of endovascular clamping as neuroprotection during carotid stenting in the presence of a critical ipsilateral stenosis of the external carotid artery. *EuroIntervention* 2008;3:588-92.
  15. Diederich KW, Scheinert D, Schmidt A, Scheinert S, Reimers B, Sievert H, et al. First clinical experiences with an endovascular clamping system for neuroprotection during carotid stenting. *Eur J Vasc Endovasc Surg* 2004;28:629-33.
  16. Coppi G, Moratto R, Silingardi R, Rubino P, Sarropago G, Salemme L, et al. PRIAMUS—proximal flow blockage cerebral protection during carotid stenting: results from a multicenter Italian registry. *J Cardiovasc Surg* 2005;46:219-27.
  17. Reimers B, Sievert H, Schuler GC, Tübler T, Diederich K, Schmidt A, et al. Proximal endovascular flow blockage for cerebral protection during carotid artery stenting: results from a prospective multicenter registry. *J Endovasc Ther* 2005;12:156-65.
  18. White CM. Thrombin-directed inhibitors: pharmacology and clinical use. *Am Heart J* 2005;149:S54-60.
  19. Erdogan HB, Goksedef D, Erentug V, Polat A, Bozbuga N, Mansuroglu D, et al. In which patients should sheathless IABP be used? An analysis of vascular complications in 1211 cases. *J Card Surg* 2006;21:342-6.
  20. Cremonesi A, Manetti R, Setacci F, Setacci C, Castrista F. Protected carotid stenting clinical advantages and complications of embolic protection devices in 442 consecutive patients. *Stroke* 2003;34:1936-43.
  21. Rao AK, Pratt C, Berke A, Jaffe A, Ockene I, Schreiber TL, et al. Thrombolysis In Myocardial Infarction (TIMI) trial—Phase I: hemorrhagic manifestations and changes in plasma fibrinogen and the fibrinolytic system in patients treated with recombinant tissue plasminogen activator and streptokinase. *J Am Coll Cardiol* 1988;11:1-11.
  22. Newcombe RG, Altman DG. Proportions and their differences. In: Altman DG, editor. *Statistics with confidence—confidence intervals and statistical guidelines*. 2nd edition. London: British Medical Journal, 2000. p. 45-56.
  23. Endovascular versus surgical treatment in patients with carotid stenosis in the Carotid and Vertebral Artery Transluminal Angioplasty Study (CAVATAS): a randomized trial. *Lancet* 2001;357:1729-37.
  24. Mas JL, Chatellier G, Beyssen B, Branchereau A, Moulin T, Becquemin JP, et al. Endarterectomy versus stenting in patients with symptomatic severe carotid stenosis. *N Engl J Med* 2006;355:1660-71.
  25. Stabile E, Salemme L, Sorropago G, Tesorio T, Nammias W, Miranda M, et al. Proximal endovascular occlusion for carotid artery stenting: results from a prospective registry of 1,300 patients. *J Am Coll Cardiol* 2010;55:1661-7.

Submitted Feb 11, 2010; accepted Jun 5, 2010.