Outcome of common iliac arteries after straight aortic tube-graft placement during elective repair of infrarenal abdominal aortic aneurysms

Réda Hassen-Khodja, MD,[a] Patrick Feugier, MD,[b] Jean-Pierre Favre, MD,[c] André Nevelsteen, MD,[d] and **José Ferreira, MD,[e] for the University Association for Research in Vascular Surgery,** *Nice, Lyon, and Saint-Etienne, France, and Leuven, Brussels, Belgium*

Purpose: **To determine the relative rates of common iliac artery (CIA) expansion after elective straight aortic tube-graft replacement of infrarenal abdominal aortic aneurysms (AAA).**

Methods: **Five participating centers in this 2004 study entered patients they had managed by an aortoaortic tube graft for elective AAA repair. The procedures took place between January 1995 and December 2003. Postoperative computed tomography (CT) scans were obtained for all patients in 2004 to assess changes in CIA diameter. Measurements on preoperative and postoperative CT scans were all made at the same level using the same technique.**

Results: **Entered in the study were 147 patients (138 men, 9 women) with a mean age of 68 years. Mean follow-up from aortic surgery to verification of CIA diameter on the postoperative CT scan was 4.8 years. Mean preoperative CIA diameter was 13.6 mm vs 15.2 mm postoperatively. No patient developed occlusive iliac artery disease during follow-up. Three patients (2%) required repeat surgery during follow-up for a CIA aneurysm. The 147 patients were divided into three groups based on preoperative CIA diameter shown in CT scan: group A (n = 59, 40.1%), both CIA were of normal diameter; group B (n = 53, 36.1%), ectasia (diameter between 12 and 18 mm) of at least one CIA; group C (n = 35, 23.8%), an aneurysm (diameter >18 mm) of at least one CIA. CIA diameter increased by a mean of 1 mm (9.4%) over 5.5 years in group A vs 1.7 mm (12.1%) over 4.3 years in group B and 2.3 mm (12.7%) over 4.2 years in group C. The three patients who required repeat surgery for a CIA aneurysm during follow-up were all in group C. Four variables were associated with aneurysmal change in CIA: initial CIA diameter, celiac aorta diameter on the preoperative CT scan, a coexisting aneurysm site, and the follow-up duration.**

Conclusions: **Tube-graft placement during AAA surgery is justified even for moderate CIA dilatation (<18 mm). CIA aneurysms with a preoperative diameter ≥25 mm enlarge more rapidly and warrant insertion of a bifurcated graft during the same surgical session as AAA repair. The evolutive potential of CIA between 18 mm and 25 mm in diameter justifies a bifurcated graft when the celiac aorta diameter is >25 mm or the patient's life expectancy is ≥8 years. (J Vasc Surg 2006;44:943-8.)**

Aortoaortic grafts have long been advocated instead of aortic bi-iliac bifurcated grafts for surgical repair of infrarenal abdominal aortic aneurysms (AAA). The literature contains numerous publications in favor of tube grafts during such procedures,[1-9] yet preferential use of tube grafts or bifurcated grafts remains controversial. The proportion of tube grafts compared with bifurcated grafts during AAA surgery varies between 0% and 85%, depending on the series.[5,9,10] There were no formally defined selection criteria for bifurcated or tube grafts.

The arguments in favor of preferential tube grafts include a shortened operation time and reduced intraoperative blood loss, especially in case of aneurysm rupture.[8] It has also been claimed that tube grafts are easier and faster to insert during elective AAA repair, and that this contributed to simplification of the surgical technique.[4,6,11] This point is currently of particular interest owing to the development of minilaparotomy techniques and coelioscopic aortic surgery. Other potential benefits of tube grafts include a lower risk of venous and ureteral injury during dissection of the common iliac arteries (CIA), a reduced risk of postoperative erectile dysfunction, and fewer postoperative graft-related complications (thrombosis, false anastomotic aneurysms).[2-4,7,8,11-13]

Proponents of bifurcated grafts point out that these prostheses permit treatment of atherosclerotic aortoiliac disease at the same time as AAA repair and that they prevent subsequent aneurysmal CIA change.[12,14,15] Furthermore, it has been suggested that the risk of aneurysmal dilatation after tube-graft replacement might offset the immediate benefits of such prostheses.

This multicenter study was conducted to determine the outcome of CIA after tube-graft placement during elective AAA repair and to identify those patients for whom the risk of aneurysmal CIA change would justify first-line placement of a bifurcated graft. The study was designed along the same lines as the one we published recently,[16] and this

From the Departments of Vascular Surgery at the University Hospital of Nice,[a] the University Hospital of Lyon,[b] the University Hospital of Saint-Etienne,[c] the Gasthuisberg Hospital of Leuven,[d] and the University Hospital of Brussels.[e]

Competition of interest: none.

Reprint requests: Prof. Réda Hassen-Khodja, Hôpital Saint Roch, Service de Chirurgie Vasculaire, 5 rue Pierre Dévoluy - BP 1319, 06006 Nice Cedex 1, France (e-mail: hassen-khodja.r@chu-nice.fr).

0741-5214/$32.00

Copyright © 2006 by The Society for Vascular Surgery.

doi:10.1016/j.jvs.2006.06.043

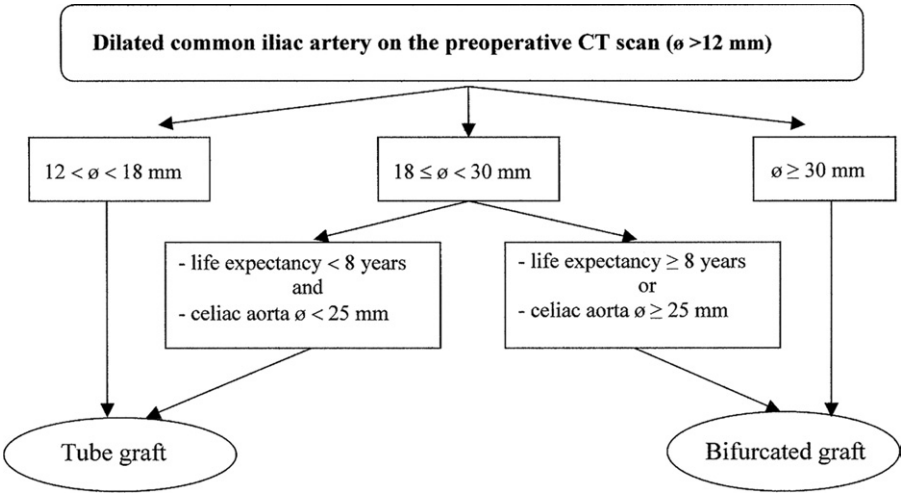

Fig 1. Previously suggested decision algorithm[16] for elective surgical repair of abdominal aortic aneurysms in patients with common iliac artery aneurysm dilatation on the preoperative computed tomography *(CT)* scan (∅, Diameter).

allowed us to verify the initial decision algorithm we proposed on the basis of our earlier findings (Fig 1).

METHODS

Five centers of the University Association for Research in Vascular Surgery (AURC) participated in this study. Each center entered patients who had received an aortoaortic tube graft for elective repair of an AAA. The procedures occurred between January 1995 and December 2003. To determine the evolution of CIA, all patients underwent a computed tomography (CT) scan during 2004. Excluded were patients for whom no preoperative CT scan was available, those who had received a bifurcated graft, and patients operated on for a ruptured aneurysm.

Information for each patient was collected using a data sheet containing 26 variables. Preoperative, perioperative, and postoperative data were recorded and analyzed using the Excel 2000 spreadsheet software program (Microsoft, Redmond, Wash). An iliac occlusive disease was sought systematically with analysis of the histories, follow-up data, physical examination, and duplex ultrasonography.

An essential feature of the study was measurement of the diameter of both CIA on the preoperative and postoperative CT scans, which can be difficult[17] owing to the often-tortuous arterial course. To our knowledge, there is no consensus for the measurement of the CIA diameter. We thought that the minor axis was not the best axis for the detection and the measurement of an aneurysm of the CIA. In this study, only the greatest transverse CIA diameter was recorded, which is not the largest distance in any direction. It was important to determine the true transverse diameter. Diameter measurements were made perpendicular to the direction of tortuosity in tortuous arteries to correct oblique axial slices. Indirect measurements of reconstructed images in three dimensions were not used for this study.

Preoperative and postoperative measurements were made using the same technique at the same level. The diameter of the celiac aorta at the origin of the superior mesenteric artery was also measured on the preoperative CT scan. The measured diameter of the celiac artery was used for comparison of the evolution of the diameter of the aorta in a nonaneurysmal zone with the evolution of the CIA. This measurement was made at the origin of the superior mesenteric artery because it is an easily located and stable anatomic landmark that allows successive measurements on the preoperative and postoperative CT scan.

Table I. Patient distribution as a function of preoperative common iliac artery diameter

CIA	*Diameter (mm)*	*Group*	*N (%)*
Normal	≤12	A	59 (40.1)
Ectatic	>12 and <18	B	53 (36.1)
Aneurysmal	≥18	C	35 (23.8)

CIA, Common iliac artery.

In this study, CIA aneurysm and ectasia were defined using the criteria of the Ad Hoc Committee on Reporting Standards of the Society for Vascular Surgery and the International Society for Cardiovascular Surgery.[18] Normal CIA diameter is 12 mm.[19] CIA were considered aneurysmal when their diameter was ≥18 mm and ectatic when their diameter was between 12 mm and 18 mm. These definitions of CIA dilatation are summarized in Table I.

Statistical analysis. Qualitative variables were compared two by two by the χ^2 test or Fisher test, as appropriate, when the theoretic sample size was <5. Variables analyzed in this manner included the distributions for histories, age and sex, the presence of polyaneurysmal disease or a coexisting aneurysm at another site, and progression or stability of the CIA diameter. Quantitative variables (diameter of the CIA, the aneurysm, the celiac aorta, and follow-up) were analyzed as a function of CIA evolution by one-way analysis of variance or the Mann-

Whitney rank test. The nonparametric Kruskal-Wallis test was used for small samples. Multivariate analysis was performed by logistic regression with progression of the CIA diameter as the dependant variable. The threshold of significance for all statistical tests was set at $P = .05$. Multiple means were compared after adjustment of the P value with the Bonferroni correction.

RESULTS

Between January 1995 and December 2003, 2052 patients underwent elective surgery for an aneurysm of the infrarenal abdominal aorta, 621 (30%) of whom were managed with a tube graft and 1431 (70%) with a bifurcated graft. Among the 621 patients who received a tube graft, 25 patients (4%) had no preoperative CT scan and 85 (14%) had no postoperative CT scan because of patient refusal, renal failure, or deterioration of general health condition. During follow-up, 188 patients died, and 176 patients were lost to follow-up and did not have a postoperative CT scan. This left 147 patients (138 men, 9 women) who were eligible for this study, all of whom underwent a postoperative follow-up CT scan in 2004. Their mean age was 68 years (range, 48 to 89 years). Eighty patients (54.4%) had arterial hypertension, 14 (9.5%) were diabetic, and 59 (40.1%) had hyperlipidemia. Tobacco use was noted for 103 patients (70%), and 27 (18.3%) had a chronic obstructive bronchopneumopathy. Sixty-four patients (43.5%) had a history of cardiac disease, 20 (13.6%) had occlusive disease of the lower limbs, and 18 (12.2%) had a history of stroke. Presence of an aneurysm at another site was not sought systematically. Nevertheless, analysis of the histories and follow-up data for the 147 patients revealed the existence of additional aneurysms in 19.

Mean follow-up from aortic surgery to verification of CIA diameter on the postoperative CT scan was 4.8 years (range, 1 to 9 years). The mean CIA diameter was 13.6 mm preoperatively vs 15.2 mm on the postoperative CT scans. Overall, the mean increase in CIA diameter was 1.6 mm (11.8%) over 4.8 years.

None of the 147 patients developed occlusive iliac artery disease during the follow-up period, but three (2%), required repeat surgery because of an increase in the size of a CIA aneurysm on the postoperative CT scan. These three patients had asymptomatic CIA aneurysms measuring >35 mm in diameter.

Three years after tube graft placement, one 78-year-old patient was found to have a left CIA aneurysm measuring 43 mm in diameter that was successfully managed by a stent graft. This aneurysm had been present before surgical AAA repair. The preoperative CT scan showed a left CIA measuring 30 mm in diameter and a celiac aorta measuring 30 mm.

In a second patient, aged 72 years, a 45-mm-diameter left CIA aneurysm developed 4 years after tube-graft placement for an AAA. Repeat surgery was performed to place an aortobiiliac bifurcated graft. This aneurysm had also been present before AAA surgery, because the left CIA measured 30 mm in diameter (Fig 2) and the celiac aorta measured 21 mm on the preoperative CT scan.

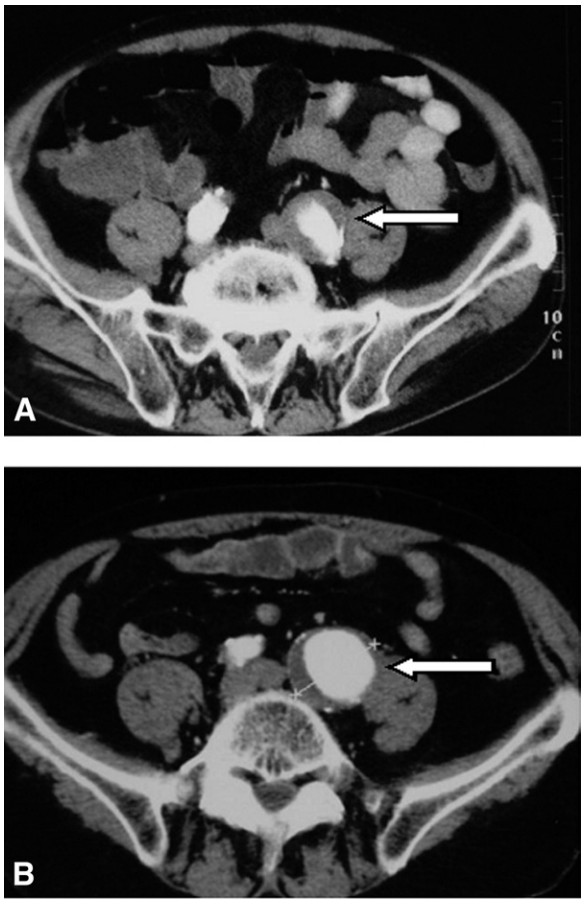

Fig 2. A, Left common iliac artery aneurysm (arrow) measuring 30 mm on the preoperative computed tomography scan. **B,** Four years after aortic tube-graft placement, the left common iliac artery aneurysm (arrow) measures 45 mm in diameter on the postoperative computed tomography scan.

A third patient, aged 72 years, had a left CIA aneurysm measuring 37 mm in diameter 8 years after tube-graft placement. The preoperative CIA scan showed a left CIA measuring 18 mm in diameter and a celiac aorta measuring 28 mm. The CIA aneurysm of this patient was successfully managed by a stent graft after embolization of the left hypogastric artery. The iliac aneurysms of all three patients were asymptomatic and were discovered incidentally.

Overall, the percentage of repeat surgery for a CIA aneurysm in our entire population was thus 2% (3/147) after a mean follow-up of 4.8 years. Had we applied the decision algorithm suggested in our earlier study (Fig 1), these three patients would have received a bifurcated graft instead of a tube graft. During the period of this study, the five participating centers reported only two iliac artery ruptures in patients who received a tube graft for an AAA.

Our patients were divided into three groups as a function of their preoperative CIA diameters (Table I). Group A consisted of the 59 patients (40.1%) in whom both CIA were normal in diameter on the preoperative CT scan.

Table II. Change in common iliac artery diameter in the three patient groups

		Mean CIA diameter (mm)				
Group	*Patients (n)*	*Preoperative*	*Postoperative*	*Evolution*	*Growth**	*Mean follow-up*
A	59	10.6	11.6	+1 mm	9.4%	5.5 years
B	53	14.1	15.8	+1.7 mm	12.1%	4.3 years
C	35	18.1	20.4	+2.3 mm	12.7%	4.2 years

CIA, Common iliac artery.
*As a percentage of initial CIA size.

Group B consisted of the 53 patients (36.1%) with ectasia (diameter between 12 mm and 18 mm) of at least one CIA on the preoperative CT scan. Group C consisted of the 35 patients (23.8%) who presented an aneurysm (diameter ≥18 mm) of at least one CIA on the preoperative CT scan.

Table II summarizes the evolution of the CIA diameter in the three patient groups. In group A (normal CIA preoperatively), the mean CIA diameter was 10.6 mm preoperatively and 11.6 mm postoperatively, for a mean increase of 1 mm (9.4%) after 5.5 years (Table II). No group A patient had a CIA >20 mm in diameter postoperatively, regardless of the duration of follow-up. In group B (ectatic CIA preoperatively), the mean CIA diameter was 14.1 mm preoperatively and 15.8 mm postoperatively. CIA diameter in this group increased by a mean of 1.7 mm (12.1%) in 4.3 years (Table II). Only three group B patients had a CIA with a postoperative diameter >20 mm (respectively, 21, 21 and 24 mm); none had a CIA with a diameter ≥25 mm. In group C (aneurysmal CIA preoperatively), the mean CIA diameter was 18.1 mm preoperatively and 20.4 mm postoperatively for a mean increase of 2.3 mm (12.7%) after 4.2 years (Table II).

The three patients who required repeat surgery for a CIA aneurysm were in group C. Six group C patients had a CIA with a postoperative diameter ≥30 mm, and four others had a CIA with a postoperative diameter of 25 mm to 30 mm. Ten of the 35 group C patients thus had a CIA with a postoperative diameter ≥25 mm after a mean follow-up of 5.6 years. Had our initial decision algorithm been applied (Fig 1), nine would have received a bifurcated graft rather than a tube graft. Two of these patients had a CIA with a preoperative diameter of 30 mm, three had a celiac aorta with a diameter ≥25 mm on the preoperative CT scan (respectively 25, 27 and 28 mm), and the other four patients had a long follow-up of 8 years. The tenth patient had a CIA of 30 mm in diameter on the postoperative CT scan after a follow-up of 6 years. On the preoperative CT scan, the celiac aorta of this patient measured 20 mm and the CIA measured 28 mm. The initial decision algorithm (Fig 1) indicated a tube graft for this patient.

Univariate and multivariate analyses were performed to identify those variables associated with CIA aneurysmal change. Variables tested included age, sex, history, initial CIA diameter, maximum AAA diameter, preoperative diameters of the inter-renal aorta and the celiac aorta, the diameter of the graft, the existence of a coexisting aneurysm, and the duration of follow-up. A statistically significant difference was observed for four variables: the initial diameter of the CIA, the diameter of the celiac aorta measured on the preoperative CT scan, the existence of another aneurysm location, and the duration of follow-up. The initial CIA diameter was highly significant (P = .0009): the larger the initial CIA diameter, the greater the postoperative increase in size. The preoperative diameter of the celiac aorta of the three patients in whom an iliac aneurysm developed postoperatively was significantly larger than that of the other patients (P = .004). The percentage of patients with a coexisting aneurysm was also greater among those patients who had an increased CIA diameter on the postoperative CT scan compared with those with a stable CIA diameter; however, this difference was statistically significant only for group C (P = .02). Not surprisingly, the longer the follow-up duration, the greater the risk of aneurysmal change (P = .007).

DISCUSSION

In this study, CIA diameter increased by a mean of 1.6 mm (11.8%) over 4.8 years after placement of a tube graft. No CIA dilatation <18 mm in diameter (groups A and B, 76.2% of the patients) ever progressed to an iliac aneurysm ≥25 mm in diameter after tube-graft insertion. Postoperative change in CIA diameter was thus very limited. These results must be interpreted with caution owing to the important selection bias in this study. Indeed, we analyzed the outcome of 147 patients selected to undergo aortic tube-graft placement that had preoperative CT scans and follow-up CT scans in 2004. These patients represent 23.7% of the 621 patients who underwent aortic tube-graft placement during the same period. The indications for the original procedures (tube graft vs bifurcated graft) were not provided. Moreover, the diameter of the CIA was measured on only two CT films (one preoperative study and one postoperative study); in addition, the interval between the two studies was variable. Under these conditions, we can only estimate the evolution of the diameter of CIA aneurysms over time.

During the period of this study, the five participating centers reported only two iliac artery ruptures in patients who received a tube graft for an AAA. But many patients in the study were lost to follow-up, and we didn't know the causes of all the deaths. So, it was impossible to know the iliac artery rupture risk for these patients. We did not know

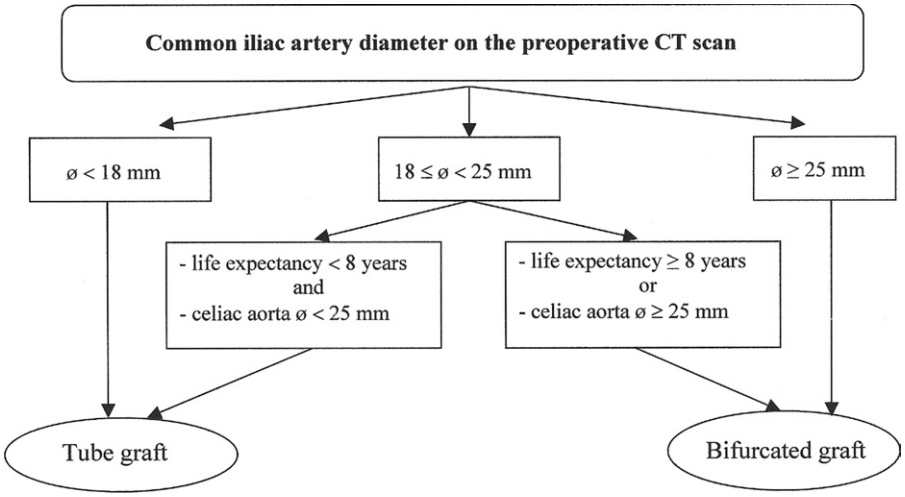

Fig 3. New decision algorithm for graft selection as a function of common iliac artery aneurysm diameter on the preoperative computed tomography *(CT)* scan (∅, Diameter).

the mean survival of these patients. The aim of this study was to estimate the evolution of the diameter of CIA over time. But the true indication for aneurysm repair is to prolong life, without rupture. So, the results of our study must be interpreted with caution.

Several factors were found to influence postoperative CIA evolution. The larger the initial CIA diameter, the greater the postoperative increase in diameter ($P = .0009$). In group A (normal CIA), CIA diameter increased by a mean of 1 mm (9.4%) over 5.5 years vs 1.7 mm (12.1%) over 4.3 years in group B (ectatic CIA) and 2.3 mm (12.7%) over 4.2 years in group C (aneurysmal CIA) (Table II). Similar findings have been reported in the literature. Dosluoglu et al[20] and Kasirajan et al[21] found that the size of CIA aneurysms <30 mm in diameter remained stable during the first 5 years after diagnosis. Santilli et al[22] reported an annual growth rate of only 1 mm for CIA aneurysms <3 cm in diameter; in contrast, the annual growth rate in their study was 2.6 mm for CIA aneurysms of 3 to 5 cm in diameter ($P < .003$).

The preoperative diameter of the celiac aorta was significantly larger in patients who developed a postoperative iliac aneurysm than in the other patients ($P = .004$). In our series, a celiac aorta diameter of ≥25 mm was thus predictive of an increase in postoperative CIA diameter.

The incidence of iliac aneurysms and AAAs discovered synchronously varies from 15% to 45%, depending on the series.[5,23] In our study, a common iliac aneurysm was noted on the preoperative CT scans of 35 patients in group C (23.8%). Three (2%) of our 147 patients underwent repeat surgery for a CIA aneurysm after a mean follow-up of 4.8 years. Two had a CIA measuring 30 mm in diameter on the preoperative CT scan. In the literature, CIA ≥30 mm in diameter have an elevated risk of rupture and warrant surgical repair.[20,21,24-27]

One of the aims of this study was to verify our initial decision algorithm (Fig 1) for selection of a tube graft or a bifurcated graft as a function of CIA diameter.[16] This initial algorithm indicated a bifurcated graft for all three of our patients who required repeat surgery for a CIA aneurysm. It similarly indicated a bifurcated graft for nine of the 10 patients with a postoperative CIA diameter of ≥25 mm. This initial decision tree algorithm was thus inappropriate in one case, because it indicated a tube graft for a patient in whom the postoperative CIA diameter increased to 30 mm (the CIA measured 28 mm in diameter on the preoperative CT scan). To render this algorithm more effective, we suggest that the threshold for indication of a bifurcated graft as first-line treatment be lowered from 30 mm to 25 mm. The new decision algorithm for graft selection as a function of CIA diameter on the preoperative CT scan is shown in Fig 3. Our algorithm of recommendations is based on arbitrary criteria (life expectancy was not an issue specifically addressed in our study), so it must be interpreted with caution.

CONCLUSION

Our study showed that tube-graft placement during AAA repair is justified even for cases of moderate CIA dilatation (<18 mm). Systematic use of bifurcated grafts thus appears unjustified. However, CIA aneurysms with a preoperative diameter ≥25 mm increase more rapidly in size and should be managed during the same surgical session as the AAA by insertion of a bifurcated graft. The evolutive potential of CIA between 18 and 25 mm in diameter justifies a bifurcated graft when the celiac aorta is >25 mm in diameter or when the patient's life expectancy is ≥8 years (Fig 3).

We thank the members of the AURC who participated in this study either by sharing their patient files or, for those who used only bifurcated grafts, by replying to inquiries. We thank Frédéric Berthier for statistical analysis of the study data and Lydie Hassen-Khodja for preparation of the manuscript. Fi-

nally, thanks go to the secretaries of the AURC, Claude Laurian, and Pierre-Edouard Magnan for their assistance in the study.

AUTHOR CONTRIBUTIONS

Conception and design: RH
Analysis and interpretation: RH
Data collection: RH, PF, JF, AN, JF
Writing the article: RH, PF
Critical revision of the article: RH, PF, JF
Final approval of the article: RH
Statistical analysis: RH, PF, JF
Obtained funding: Not applicable
Overall responsibility: RH

REFERENCES

1. Calcagno D, Hallett JW Jr, Ballard DJ, Naessens JM, Cherry KJ Jr, Gloviczki P, et al. Late iliac artery aneurysms and occlusive disease after aortic tube grafts for abdominal aortic aneurysm repair. A 35-year experience. Ann Surg 1991;214:733-6.
2. Evans WE, Hayes JP. Tube graft replacement of abdominal aortic aneurysm. Am J Surg 1988;156:119-21.
3. Friedman SG, Hardaway MY, Jurkiewicz AJ, Krishnasastry KV, Doscher W, Deckoff SL, et al. Late results of preferential use of tube versus bifurcation grafts for abdominal aortic aneurysmectomy. Ann Vasc Surg 1990;4:39-41.
4. Glickman MH, Julian CC, Kimmins S, Evans WE. Aortic aneurysm: to tube or not to tube. Surgery 1982;91:603-5.
5. Lavee J, Schneiderman J, Bass A, Amsterdam E, Walden R, Adar R. Tube graft replacement of abdominal aortic aneurysm: is concomitant iliac disease a contraindication? J Cardiovasc Surg 1988;29:449-52.
6. Orr WM, Davies M. Simplified repair of abdominal aortic aneurysms using non-bifurcated (straight) inlay prostheses. Br J Surg 1974;61: 847-9.
7. Provan JL, Fialkov J, Ameli FM, St Louis EL. Is tube repair of aortic aneurysm followed by aneurysmal change in the common iliac arteries? Can J Surg 1990;33:394-7.
8. Snellen JP, Terpstra OT, van Urk H. The use of a straight tube graft decreases blood loss and operation time in patients with an abdominal aortic aneurysm. Neth J Surg 1984;36:45-7.
9. Wilson SE, White G, Williams RA. Straight segmental versus bifurcation grafts for repair of abdominal aortic aneurysm. Cardiovasc Surg 1993; 1:23-6.
10. Biancari F, Ylonen K, Anttila V, Juvonen J, Romsi P, Satta J, et al. Durability of open repair of infrarenal abdominal aortic aneurysm: a 15-year follow-up study. J Vasc Surg 2002;35:87-93.
11. Branchereau A, Nazet J, Colavolpe JC, Scotti L. Combined mortality and morbidity of direct surgical treatment of abdominal aortic aneurysm. Ann Vasc Surg 1990;4:10-4.
12. Purdy RT, Beyer FC 3rd, McCann WD, Smith ID, Mann RH. Reduced aortic cross-clamp time in high-risk patients with abdominal aortic aneurysm. J Vasc Surg 1986;3:820-3.
13. Yasuhara H, Shigematsu H, Muto T. Advantages of straight graft for abdominal aortic aneurysm repair. Panminerva Med 1998;40:199-203.
14. Plate G, Hollier LA, O'Brien P, Pairolero PC, Cherry KJ, Kazmier FJ. Recurrent aneurysms and late vascular complications following repair of abdominal aortic aneurysms. Arch Surg 1985;120:590-4.
15. Kalman PG, Rappaport DC, Merchant N, Clarke K, Johnston KW. The value of late computed tomographic scanning in identification of vascular abnormalities after abdominal aortic aneurysm repair. J Vasc Surg 1999;29:442-50.
16. Sala F, Hassen-Khodja R, Branchereau P, Berthet JP, Batt M, Mary H, et al. Outcome of common iliac arteries after aortoaortic graft placement during elective repair of infrarenal abdominal aortic aneurysms. J Vasc Surg 2002;36:982-7.
17. Lal BK, Cerveira JJ, Seidman C, Haser PB, Kubicka R, Jamil Z, et al. Observer variability of iliac artery measurements in endovascular repair of abdominal aortic aneurysms. Ann Vasc Surg 2004;18:644-52.
18. Johnston KW, Rutherford RB, Tilson MD, Shah DM, Hollier L, Stanley JC. Suggested standards for reporting on arterial aneurysms. J Vasc Surg 1991;13:452-8.
19. Horejs D, Gilbert PM, Burstein S, Vogelzang RL. Normal aortoiliac diameters by CT. J Comput Assist Tomogr 1988;12:602-3.
20. Dosluoglu HH, Dryjski ML, Harris LM. Isolated iliac artery aneurysms in patients with or without previous abdominal aortic aneurysm repair. Am J Surg 1999;178:129-32.
21. Kasirajan V, Hertzer NR, Beven EG, O'Hara PJ, Krajewski LP, Sullivan TM. Management of isolated common iliac artery aneurysms. Cardiovasc Surg 1998;6:171-7.
22. Santilli SM, Wernsing SE, Lee ES. Expansion rates and outcomes for iliac artery aneurysms. J Vasc Surg 2000;31:114-21.
23. Timaran CH, Lipsitz EC, Veith FJ, Chuter T, Greenberg RK, Ohki T, et al; for the Zenith investigators. Endovascular aortic aneurysm repair with the Zenith endograft in patients with ectatic iliac arteries. Ann Vasc Surg 2005;19:161-6.
24. Desiron Q, Detry O, Sakalihasan N, Defraigne JO, Limet R. Isolated atherosclerotic aneurysms of the iliac arteries. Ann Vasc Surg 1995; 9 Suppl:S62-6.
25. Kanazawa S, Inada H, Murakami T, Tabuchi A, Ishida A, Tsunoda T. Management of isolated iliac artery aneurysms. J Cardiovasc Surg 2000;41:513-4.
26. Krupski WC, Selzman CH, Floridia R, Strecker PK, Nehler MR, Whitehill TA. Contemporary management of isolated iliac aneurysms. J Vasc Surg 1998;28:1-13.
27. Weimann S, Tauscher TH, Flora G. Isolated iliac artery aneurysm. Ann Vasc Chir 1990;4:297-301.

Submitted Apr 22, 2006; accepted Jun 10, 2006.